

Vasoactive Intestinal Peptide and Somatostatin Receptor Scintigraphy for Differential Diagnosis of Hepatic Carcinoid Metastasis

Amir Kurtaran, Markus Raderer, Christian Müller, Rupert Prokesch, Klaus Kaserer, Klemens Eibenberger, Katharina Koperna, Bruno Niederle and Irene Virgolini

Departments of Nuclear Medicine, Gastroenterology, Radiology, Clinical Pathology and General Surgery, University of Vienna, Vienna, Austria

We report a case of a hepatic carcinoid metastasis mimicking a hemangioma on ultrasound and on CT. Indium-111-DTPA-D-Phe-1-octreotide ($^{111}\text{In-OCT}$) and ^{123}I -vasoactive intestinal peptide ($^{123}\text{I-VIP}$) receptor images suggested a carcinoid metastasis of the liver. The final diagnosis was established histopathologically. The differential diagnosis of liver lesions is discussed.

Key Words: liver carcinoid metastasis; iodine-123-vasoactive intestinal peptide; indium-111-DTPA-D-Phe-1-octreotide; hemangioma

J Nucl Med 1997; 38:880-881

Despite recent advances, the differential diagnosis of focal liver lesions continues to present a diagnostic challenge, especially with ultrasound (US), computed tomography (CT) and magnetic resonance imaging (MR). The distinction between cavernous hemangiomas and hepatic metastases spread from endocrine tumors may be difficult as these metastatic lesions may be hypervascular and have similar signal intensity as hemangiomas (1-5). During the past few years, receptor-based radioligands, $^{111}\text{In-DTPA-D-Phe-1-octreotide}$ ($^{111}\text{In-OCT}$) and ^{123}I -vasoactive intestinal peptide ($^{123}\text{I-VIP}$), have been successfully used to localize primary endocrine tumors as well as metastatic liver lesions (6,7). We report a case of a carcinoid liver metastasis mimicking a hemangioma on US and CT, which could be correctly diagnosed by receptor imaging using $^{123}\text{I-VIP}$ and $^{111}\text{In-OCT}$.

CASE REPORT

A 68-yr-old woman was admitted to the hospital in May 1995 suffering from increasing abdominal pain and clinical symptoms of an obstructive ileus. Surgery revealed a carcinoid tumor (1.5 cm) located in the small intestine with mesenteric lymph-node metastases as the underlying cause. The patient underwent partial resection of the small intestine. Histologic examination of the surgical specimen demonstrated complete removal of the local malignant tissue. Two weeks later, US revealed a hyperechoic liver lesion in segment VI/VII (3.3 cm in diameter) considered to be suspicious for a hemangioma (Fig. 1). During routine follow-up, performed 4 mo after surgery, US of the liver repeatedly revealed the same lesion. Because of the patient's history and a slightly elevated urinary 5-hydroxy-indolacetic-acid (HIAA), further diagnostic work-up, including CT, was performed.

Despite the biochemical suspicion of a metastatic carcinoid tumor, CT also suggested a liver hemangioma in accordance with the sonographic finding, as the lesion showed the hypervascularization with nodular peripheral enhancement (Fig. 2). Receptor-

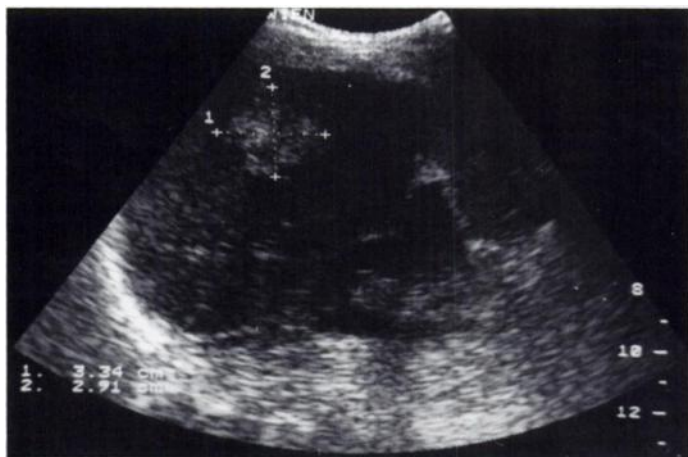

FIGURE 1. Sonographic finding indicates the hyperechoic liver lesion suspicious of a hemangioma.

based nuclear medicine imaging procedures were performed in October 1995 to evaluate the extent of the disease (6,7). Immediately after injection of 150 MBq $^{123}\text{I-VIP}$ (1 μg ; 300 pmol) dynamic studies of the abdomen and at 2 hr planar scintigraphy in anteroposterior view as well as SPECT of the liver were performed. A focally increased accumulation in the right liver lobe, corresponding to the US/CT lesion was demonstrable, indicating an increased expression of VIP receptors (7). Additionally, somatostatin receptor scanning (SST) performed with 130 MBq $^{111}\text{In-OCT}$ (6) indicated an increased focal uptake in the right liver lobe at 6 and 24 hr after injection (Fig. 3). As an increased VIP/SST receptor expression was highly suspicious for metastatic liver spread (6,7) a CT-guided, fine-needle biopsy was performed, which revealed the diagnosis of a carcinoid metastasis. The solitary liver lesion was removed by surgery. Repeated SST receptor scintigraphy performed after surgical resection revealed no evidence for focal lesions.

DISCUSSION

Cavernous hemangiomas are the most common benign liver tumors (8,9). Most commonly, they are solitary, smaller than 3 cm and appear as a well-defined hyperechoic mass on US (1). With the addition of SPECT, $^{99\text{m}}\text{Tc}$ -labeled red blood cell scintigraphy ($^{99\text{m}}\text{Tc-RBC}$) is very sensitive and highly specific for hemangiomas; however, false-negative $^{99\text{m}}\text{Tc-RBC}$ studies for hemangiomas have been reported (10,11). Using single-pass, contrast-enhanced CT, differentiation of cavernous hemangiomas from hepatic metastasis may be possible (12). The value of MR imaging of these tumors have also been well assessed (13-15). Since metastases from endocrine tumors may also have similar patterns in US, CT and MR imaging, the distinction between cavernous hemangiomas and hepatic me-

Received May 29, 1996; revision accepted Oct. 23, 1996.

For correspondence or reprints contact: Irene Virgolini, MD, Department of Nuclear Medicine, University of Vienna, Währinger Gürtel 18-20, Ebene 3L, A-1090 Vienna, Austria.

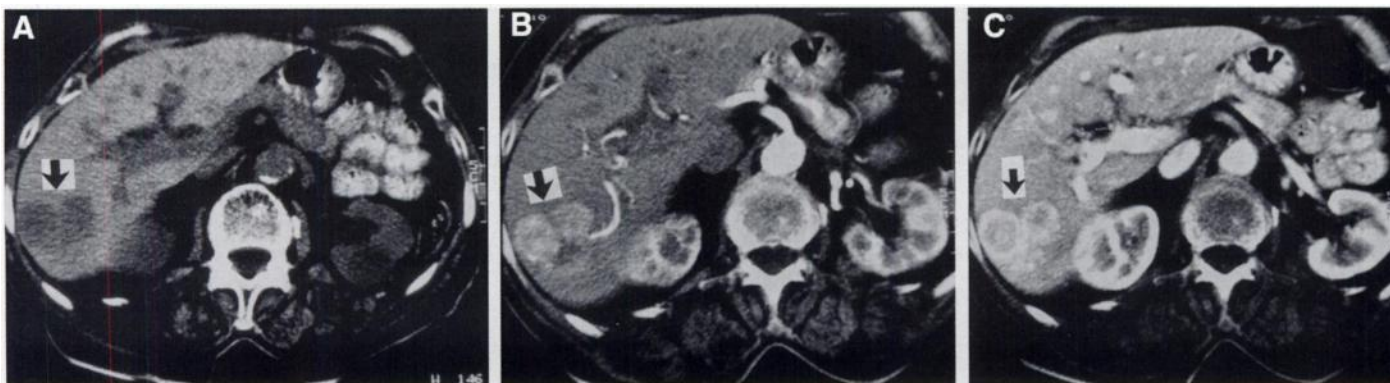

FIGURE 2. A 68-yr-old woman with hepatic carcinoid metastasis. CT scan of the liver shows a hypervascular lesion. The pattern of peripheral enhancement was suggestive for a hemangioma rather than a metastasis. (A) Native CT. (B) Contrast-enhanced CT, arterial phase. (C) Contrast-enhanced CT, portal venous phase.

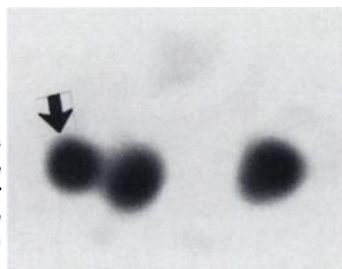


FIGURE 3. Indium-111-OCT (130 MBq, 6 hr SPECT image, transverse slice) shows focally increased tracer uptake in the right liver lobe (arrow) corresponding to the liver lesion seen on CT.

tastases can be difficult (2,4,5). Recently, ^{111}In -OCT and ^{123}I -VIP receptor scans were successfully applied for the localization of primary and metastatic carcinoid tumors, and they can be used for the staging procedure of neuroendocrine tumors (6,7). In our patient, the diagnosis of a hemangioma on US and CT was not convincing because of the patient's history and the elevated HIAA. Iodine-123-VIP and ^{111}In -OCT receptor scans demonstrated a focal lesion in the liver indicating VIP/SST receptor overexpression and thus metastatic liver spread (6,7). A carcinoid metastasis could be confirmed by histopathology. The scintigraphic results led to successful surgical resection of the tumor.

CONCLUSION

This case illustrates that carcinoid liver spread may mimic a hemangioma on US and CT. Additionally, ^{111}In -OCT/ ^{123}I -VIP receptor scans are useful in the differential diagnosis of liver lesions in patients with neuroendocrine tumors.

REFERENCES

- Bennett WF, Bowa JG. Review of hepatic imaging and problem-oriented approach to liver masses. *Hepatology* 1990;12:761-775.
- Andersson T, Eriksson B, Hemmingsson A, Lindgren PG, Öberg K. Angiography, computed tomography, magnetic resonance imaging and ultrasonography in the detection of liver metastases from endocrine gastrointestinal tumors. *Acta Radiology* 1987;5:535-539.
- Reinhold C, Hammers L, Taylor CR, et al. Characterization of focal hepatic lesions with duplex sonography. *Am J Roentgenol* 1995;164:1131-1135.
- Rummeny E, Saini S, Wittenberg J, et al. MR imaging of liver neoplasms. *Am J Roentgenol* 1989;152:493-499.
- King CL, Glazer GM, Quint LE, et al. Distinction of hepatic cavernous hemangioma from hepatic metastases with MR imaging. *Radiology* 1988;169:409-415.
- Kwekkeboom DJ, Krenning EP, Bakker WH, et al. Somatostatin analogue scintigraphy in carcinoid tumors. *Eur J Nucl Med* 1993;20:283-292.
- Virgolini I, Raderer M, Kurtaran A, et al. Vasoactive intestinal peptide-receptor imaging for the localization of intestinal adenocarcinomas and endocrine tumors. *N Engl J Med* 1994;331:1116-1121.
- Ishak KG, Rabin L. Benign tumors of the liver. *Med Clin North Am* 1975;59:995-998.
- Lombardo DM, Baker ME, Spritzer CE, et al. Hepatic hemangiomas versus metastases: MR differentiation at 1.5 T. *Am J Roentgenol* 1990;155:55-59.
- Brodsky RI, Freidman, Maurer AH, et al. Hepatic cavernous hemangioma: diagnosis with $^{99\text{m}}\text{Tc}$ -labeled red cells and SPECT. *Am J Roentgenol* 1987;148:125-129.
- Tumeh SS, Benson C, Nagel JS, et al. Cavernous hemangioma of the liver: detection with single-photon emission computed tomography. *Radiology* 1987;164:353-356.
- Leslie DF, Johnson CD, Johnson CM, et al. Distinction between cavernous hemangiomas of the liver and hepatic metastases on CT: value of contrast enhancement patterns. *Am J Roentgenol* 1995;164:625-629.
- Stark DD, Felder RC, Wittenberg J, et al. Magnetic resonance imaging of cavernous hemangioma of the liver: tissue-specific characterization. *Am J Roentgenol* 1985;145:213-222.
- Itai Y, Ohtomo K, Furui S, et al. Noninvasive diagnosis of small cavernous hemangioma of the liver: advantage of MRI. *Am J Roentgenol* 1985;145:1195-1199.
- Li KC, Glazer GM, Leslie EQ, et al. Distinction of hepatic cavernous hemangioma from hepatic metastases with MR imaging. *Radiology* 1988;169:409-415.