

Rest-Redistribution Thallium-201 and Rest Technetium-99m-Sestamibi SPECT in Patients with Stable Coronary Artery Disease and Ventricular Dysfunction

Claudio Marcassa, Michele Galli, Alberto Cuocolo, Francesco Scappellato, Simone Maurea and Marco Salvatore
S. Maugeri Foundation IRCCS, Veruno and Federico II University, Naples, Italy

Resting sestamibi uptake was compared with ^{201}Tl rest-redistribution uptake in 48 patients with ischemic heart disease and regional ventricular asynergies. **Methods:** In 48 patients, rest/4-hr redistribution ^{201}Tl and resting sestamibi tomography were closely performed on separate days. Segmental tracer uptake was quantified. Wall motion in corresponding segments was also assessed by two-dimensional echocardiography in 17 patients. **Results:** Quantitative analysis indicates that the uptake of the two tracers was comparable in normal segments as well as in segments with fixed ^{201}Tl defects. In contrast, in segments with reversible ^{201}Tl defects, sestamibi uptake was significantly lower than redistribution ^{201}Tl uptake. **Conclusion:** In patients with chronic ischemic heart disease and regional asynergies, quantified sestamibi activity parallels ^{201}Tl redistribution activity in normal segments and in those with fixed ^{201}Tl defects. In segments showing reversible ^{201}Tl defects, whether or not dysfunctioning, sestamibi uptake is significantly lower than ^{201}Tl redistribution.

Key Words: coronary artery disease; myocardial infarction; thallium 201; technetium-99m-sestamibi; SPECT

J Nucl Med 1997; 38:419-424

In patients with chronic coronary artery disease, the distinction between dyssynergic but viable myocardium and scarred tissue is of clinical relevance, particularly when revascularization procedures are indicated. Many techniques have been used to identify the dysfunctioning myocardial regions which contraction may improve after revascularization (1,2). Thallium-201 myocardial imaging has been found to provide reliable information regarding both residual ischemia and myocardial viability (3-6). The accuracy of ^{201}Tl imaging in assessing myocardial viability has recently been enhanced by modified imaging protocols, including late redistribution (7), tracer reinjection (4) and rest-redistribution imaging (3,5).

Sestamibi is a technetium-labeled perfusion tracer with more favorable imaging characteristics than ^{201}Tl . Sestamibi uptake and retention have been observed to correlate with regional myocardial blood flow and tissue viability (8,9). Most of the experimental studies assessing sestamibi uptake and retention have been performed in isolated cultured myocardial cells or in animal models of coronary occlusion-reperfusion in which blood flow and delivery of the tracer are different from the clinical setting. Indeed, the issue of whether resting sestamibi myocardial uptake in humans reflects viability beyond coronary blood flow distribution is now extensively debated (10-12).

A few studies have compared regional ^{201}Tl and sestamibi uptake in humans but with diverging results (10,13-15). To

provide further insight, in this collaborative study regional ^{201}Tl and sestamibi uptake at rest were quantitatively assessed in patients with chronic coronary artery disease and ventricular dysfunction.

MATERIALS AND METHODS

Study Cohort

We studied 48 consecutive patients (57 ± 10 yr) with a history of previous myocardial infarction and wall motion abnormalities who were referred to the nuclear cardiology laboratories of the two institutions participating in the study. All patients underwent rest-redistribution ^{201}Tl and resting sestamibi tomographic studies on separate days within the same period of hospitalization and in random order. All patients were clinically stable between the two scintigraphic studies; their cardioactive therapy remained unchanged and was not withheld before the two studies. Patients with unstable angina, recent (<3 mo) myocardial infarction or overt heart failure were excluded. Coronary angiography was performed in all patients. All 17 patients from one of the two institutions also underwent evaluation of resting regional ventricular function by two-dimensional echocardiography. Patients from the two institutions were comparable in terms of age, extent of underlying coronary disease and degree of left ventricular dysfunction. The study protocol was approved by the local Ethics Committee for Human Research. Informed consent was obtained from all patients.

Thallium and Sestamibi Imaging Protocols

Patients received ^{201}Tl (111 MBq) and sestamibi (13 MBq/kg) injections at rest, within two to six days of each other, and in each case after an overnight fast. To minimize gallbladder activity, patients were instructed to consume a fatty meal after the sestamibi injection. Thallium-201 images were obtained 15 min and 4 hr after injection; sestamibi images were acquired on average 60-90 min after injection. A large field of view rotating camera (Apex-409 or Apex SP4-HR, Elscint, Israel, depending on the institution) equipped with a low-energy, parallel-hole collimator was used. The imaging was performed over a 180° semicircular orbit, in a step-and-shoot mode. Data were collected in a 64×64 array. Particular care was taken to avoid major artifacts, such as patient motion, during acquisition.

Tomographic Image Analysis

Transaxial slices were reconstructed using a backprojection algorithm with a low-resolution Butterworth filter (cutoff frequency of 0.5 cycles/pixel and a 5.0 order) in the 31 (65%) patients imaged by the SP4-HR system and a modified Wiener filter (dumping factor of 1.0 for ^{201}Tl and 0.8 for $^{99\text{m}}\text{Tc}$) in the remaining 17 patients imaged by the Apex-409 system. No attenuation or scatter correction were used; flood correction was applied during reconstruction. From the transaxial slices, ventricular sections in

Received Mar. 12, 1996; revision accepted Jun. 15, 1996.

For correspondence or reprints contact: Claudio Marcassa MD, Cardiology Division, Fondazione S. Maugeri IRCCS, Via Revisiate 13, Veruno 28010 (No), Italy.

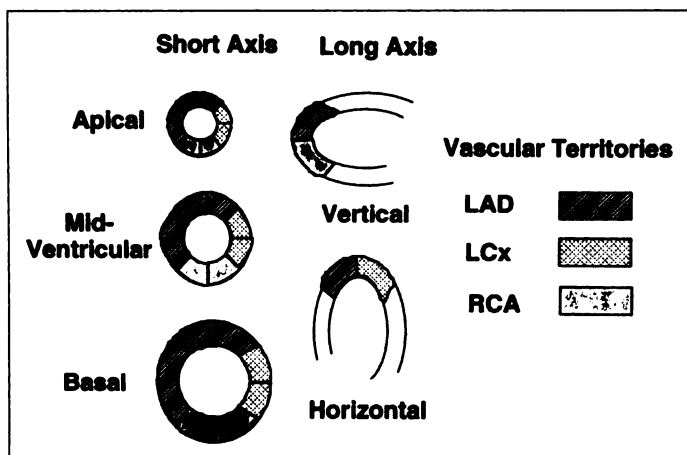


FIGURE 1. Diagram of the segmentation scheme used for regional ^{201}Tl and sestamibi uptake and corresponding assignment to one of the major coronary vascular territories.

the horizontal and vertical long axis and in the short axis views were reconstructed.

For the quantitation of regional tracer uptake defects, three representative slices from the short-axis view (apical, midventricular and basal) and the midventricular slices in the horizontal and vertical long-axis views were considered. In the short-axis view, the apical slice was chosen by selecting the distal slice where the left ventricular cavity was first visible; the basal slice was chosen by selecting the slice in which a decrease in the septal activity was first visualized and by moving one to two slices further toward the apex, and the midventricular slice was chosen halfway between the apical and basal slices. Tomograms were divided into 22 (6 proximal, 6 midventricular, 6 distal and 4 apical) segmental ROIs (Fig. 1). In each patient, corresponding rest-redistribution ^{201}Tl and sestamibi mean segmental uptake were evaluated for direct comparison. In each tomographic slice, the myocardial segment with the maximum counts was taken as the normal reference; relative ^{201}Tl and sestamibi uptake in the other segments of the slice were expressed as a percentage of this reference segment.

Segmental ^{201}Tl and sestamibi uptake was considered abnormal if it was $<75\%$ of peak myocardial activity; the segmental defect was classified as severe if the tracer uptake was $<50\%$ and mild-moderate if 50% to 75% of peak myocardial activity. A ^{201}Tl defect was considered reversible when its abnormal tracer uptake on rest images increased $>10\%$ on redistribution images (4,15).

Regional Wall Motion Assessment

Seventeen (35%) patients, all from the same institution, also underwent a complete echocardiographic study in multiple views with a commercially available imaging system. The three apical views (four- and two-chamber and long-axis) were analyzed. The left ventricle was divided into 22 segments to match the same left ventricular segmentation used during ^{201}Tl and sestamibi tomography (Fig. 1). Systolic wall thickening and inward wall motion were assessed visually off-line by two experienced technologists who were unaware of other information. In each segment, contraction was graded on a four-point scoring system (0 = normal; 1 = hypokinetic; 2 = akinetic and 3 = dyskinetic). In cases of discrepancies (9% of analyzed segments), a consensus was reached.

Coronary Angiography

After intracoronary nitroglycerin administration, selective angiograms were obtained in at least two projections for the right coronary artery and at least four for the left coronary artery. The presence of a significant ($>50\%$ coronary diameter reduction) stenosis was assessed by caliper measurements in two orthogonal

TABLE 1
Demographic Data of the Study Cohort

Age (yr)	57 \pm 10
Gender (M/F)	45/3
History of:	
Effort angina	36 (75%)
Anterior MI	30 (63%)
Inferior MI	13 (27%)
Coronary angiography:	
One-vessel disease	15 (31%)
Two-vessel disease	17 (35%)
Three-vessel disease	16 (34%)
Ejection fraction (%)	39 \pm 15

MI = myocardial infarction. Data are expressed as mean \pm 1 s.d. or frequency (%).

projections by one experienced observer who was unaware of other information. The vascular attribution of scintigraphic segments to the conventional anatomic distribution of the major coronary arteries was performed according to the division proposed by the Cedars-Sinai Laboratory (16). The thrombolysis in myocardial infarction (TIMI) grade of the scintigraphic defect-related vessel flow and the presence of collateral circulation were also assessed. A TIMI grade of 0-2 defined a nonpatent artery; a defect-related vessel without significant stenosis or with a TIMI grade flow of 3 defined a patent artery. Coronary collateral vessels were graded as poor (absent or faint contralateral filling) or good (dense contralateral filling).

Statistical Analysis

Data are reported as mean \pm s.d. Normality of the data distribution was verified. Student's t-test for unpaired data or one-way ANOVA for factorial analysis was used to test differences between groups; ANOVA for repeated measures combined with Scheffé's F-test was used to compare tracers uptake (rest and redistribution ^{201}Tl and resting sestamibi). The chi-square test was used to determine the significance of differences in rates of occurrence. To assess agreement between segmental ^{201}Tl and sestamibi uptake, the (κ) statistic was used. Linear regression analysis was used to assess the correlation between segmental tracer uptake. A p value <0.05 (two-tailed) was considered significant.

RESULTS

The history and clinical findings of the study cohort are reported in Table 1. At coronary angiography, all patients showed significant coronary stenoses: single and multivessel coronary disease was documented in 15 (31%) and 33 (69%) patients, respectively.

A total of 1056 myocardial segments were analyzed. Normal and abnormal sestamibi uptake was found in 469 (44%) and 587 (56%) myocardial segments, respectively; normal and abnormal resting ^{201}Tl uptake was documented in 505 (48%) and 551 (52%) segments (ns), respectively. Of the 551 segments with abnormal tracer uptake on resting ^{201}Tl images, 369 (67%) segments showed a fixed defect and 182 (33%) a reversible defect. Of these latter, the tracer redistribution was complete in 71 (39%) and incomplete in 111 (61%). No significant differences were found between abnormal ^{201}Tl segments with and without tracer redistribution regarding the patency of the defect-related vessel (TIMI Grade 3 in 68% versus 67%, respectively), its mean luminal diameter reduction ($67\% \pm 39\%$ versus $70\% \pm 30\%$), and the presence of good collaterals toward the defect-related vessel (24% versus 24%).

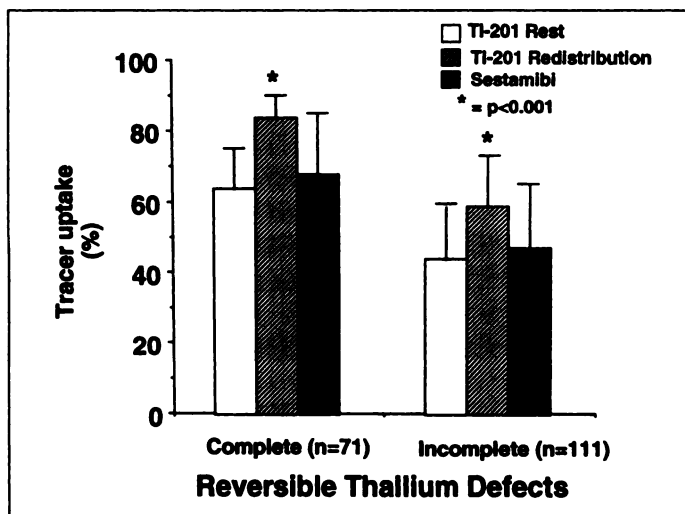


FIGURE 2. Bar graph showing ^{201}Tl and sestamibi uptake in segments with ^{201}Tl uptake defects after resting injection and either complete or incomplete reversibility on redistribution images. In both conditions, sestamibi uptake was comparable to resting and significantly lower than redistribution ^{201}Tl uptake.

Thallium-201 versus Sestamibi Uptake

Among the 505 normal ^{201}Tl segments, ^{201}Tl uptake at rest ($90\% \pm 9\%$) and redistribution ($87\% \pm 12\%$) was comparable with the sestamibi uptake ($87\% \pm 15\%$; $p = \text{ns}$). Of 369 segments with a fixed ^{201}Tl uptake defect, mean redistribution ^{201}Tl and sestamibi uptake were comparable ($49\% \pm 15\%$ versus $48\% \pm 16\%$, $p = \text{ns}$). In the 182 abnormal segments with reversible ^{201}Tl defects, sestamibi uptake was slightly greater than resting thallium uptake ($55\% \pm 20\%$ versus $52\% \pm 16\%$, $p < 0.05$), but significantly lower than redistribution thallium uptake ($68\% \pm 17\%$, $p < 0.001$) both in segments showing complete and incomplete thallium redistribution (Figs. 2, 3). Figure 4 shows the correlation between quantitative tracer uptake in matched segments with fixed and reversible ^{201}Tl defects: tracer uptake correlated less in segments with reversible than in those with fixed ^{201}Tl defects.

We used a 3×3 table to evaluate the agreement between regional ^{201}Tl uptake during redistribution imaging and sestamibi uptake (Fig. 5) and obtained a concordance in 74% of segments ($k = 0.59$). If, on the one hand, there were only 111 of 1056 (10%) segments with severely reduced sestamibi which were either normal or mild-moderate on redistribution thallium, on the other hand, this disagreement affected 111 of 283 severe sestamibi defects (39%) and involved 35 of 48 patients (73%).

Tracer uptake was comparable in 80% of segments with both normal or fixed ^{201}Tl defects, while ^{201}Tl uptake on redistribution images was greater than sestamibi in more than half of the segments showing reversible ^{201}Tl defects (Fig. 6). No significant angiographic differences were found in segments with concordant or discordant tracer uptake regarding patency (TIMI Grade 3 in 72% and 73%, respectively), mean luminal diameter reduction ($67\% \pm 39\%$ versus $70\% \pm 30\%$) or collaterals (19% and 18%, respectively) of the defect-related vessels.

Segmental Contraction and Tracers Uptake

In the 17 patients with a complete echocardiographic study, the average wall motion abnormality score was 0.63 ± 0.76 in segments with normal ^{201}Tl uptake and was 1.06 ± 1.0 and 1.31 ± 1.04 , respectively, in segments with reversible and fixed ^{201}Tl defects ($p < 0.01$). The wall motion abnormality score was lower in segments showing complete than in those showing incomplete ^{201}Tl redistribution (0.38 ± 0.77 versus 1.43 ± 0.99 ; $p < 0.01$). No significant difference concerning wall motion score was found in segments with discordant tracer uptake, whether sestamibi was greater or lower than ^{201}Tl uptake (wall motion score 0.78 ± 0.97 and 0.81 ± 1.00 , respectively).

Figure 7 shows the mean segmental ^{201}Tl and sestamibi uptake according to the corresponding wall motion pattern: sestamibi uptake was significantly lower than ^{201}Tl , irrespective of the presence or absence of severe segmental contraction abnormalities.

DISCUSSION

We compared resting regional uptake of sestamibi with ^{201}Tl uptake at rest and redistribution in patients with chronic coronary artery disease and ventricular dysfunction. Results from quantitative analysis indicate that resting sestamibi uptake parallels redistribution ^{201}Tl uptake in myocardial segments with normal as well as fixed ^{201}Tl defects. In contrast, sestamibi uptake was reduced in segments showing reversible ^{201}Tl defects. Better wall motion was also observed in segments showing reversible ^{201}Tl defects, suggesting residual viability.

Resting Hypoperfusion and Reversible Thallium-201 Defect

The presence of hypoperfused viable myocardium distal to severe coronary stenoses in the absence of other signs or symptoms of myocardial ischemia has been extensively documented (17-21). Thallium-201 redistribution in myocardial segments showing reduced resting tracer uptake reflects the presence of viable myocardium and is associated with improved contractile function after revascularization (3-5). The phenom-

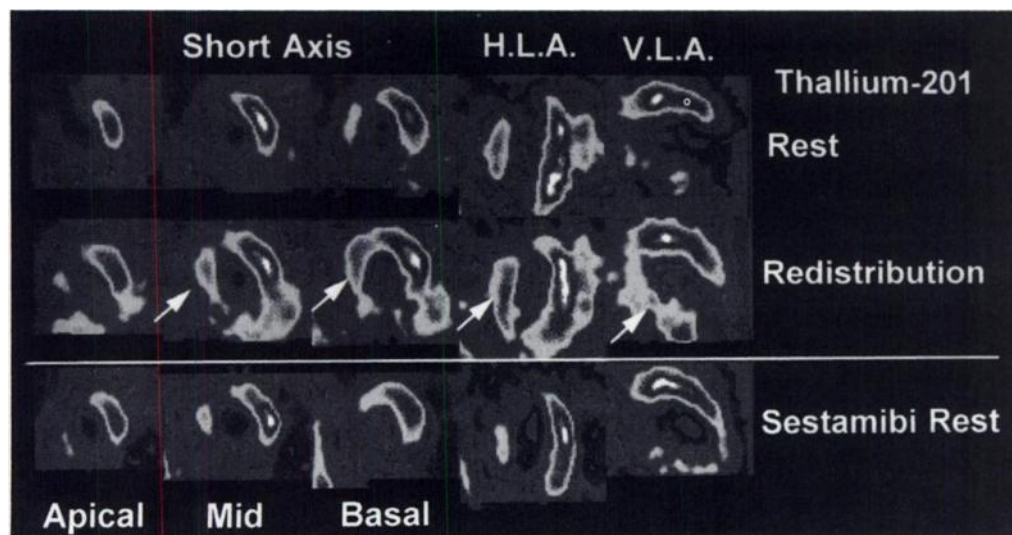


FIGURE 3. Thallium-201 rest-redistribution (upper) and sestamibi (lower) images in a patient with previous inferior and apical infarction and critically stenosed left anterior descending and circumflex arteries. Short-axis, vertical (VLA) and horizontal (HLA) long-axis images are shown. A reversible ^{201}Tl defect is evident in the septal and inferior segments (white arrows) where sestamibi uptake is severely reduced.

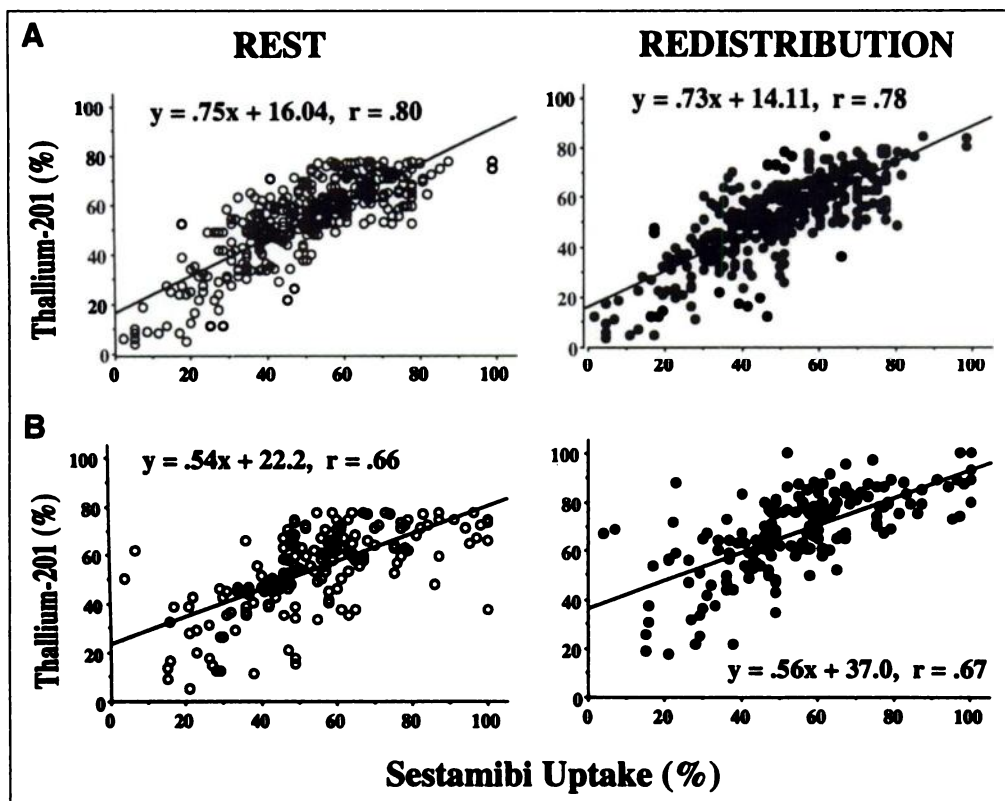


FIGURE 4. Scatterplots showing linear relation between quantitative sestamibi uptake (x-axis) and ^{201}Tl uptake (y-axis) at rest (open circles) and redistribution (closed circles) in matched myocardial segments with (A) fixed and (B) reversible ^{201}Tl defects. In the latter, despite similar angular coefficients (0.54 and 0.56, respectively), the intercept values at rest and redistribution are definitely different.

enon of ^{201}Tl rest-redistribution is well described and relates to a sustained resting low-flow condition in the presence of a critical coronary stenosis (5). Thallium-201 redistribution is also greatly influenced by the tracer serum concentration and the rate of its delivery in the redistribution period. Thus, even in the absence of substantial changes in myocardial blood flow, the lack of ^{201}Tl redistribution in noninfarcted areas may be due to the low availability of circulating tracer during the postinjection period (22–24).

Previous Results of Sestamibi Versus Thallium-201 Uptake

Despite similar myocardial distribution of sestamibi and ^{201}Tl early after injection, sestamibi is intracellularly trapped and more quickly cleared from the blood, resulting in lower plasma levels than with ^{201}Tl (25). Thus, tracer delivery into regions with severely reduced resting perfusion could be hampered.

Indeed, sestamibi redistribution over time is markedly less than that of ^{201}Tl (10,25), and in several patients with stable coronary disease, resting sestamibi uptake has been found reduced both in segments with normal wall motion as well as in asynergic regions still containing viable tissue (11,12,14,26). In myocardial segments supplied by severely stenotic coronary arteries, a significantly higher ^{201}Tl than sestamibi uptake was found by Maurea et al. (27) and by Marzullo et al. (14). At odds with these findings, Udelson et al. found that sestamibi uptake 1 hr after resting injection paralleled redistribution ^{201}Tl activity in patients with chronic ischemic ventricular dysfunction. Furthermore, they also observed a comparable accuracy of the two tracers for predicting recovery of dysfunctioning segments after revascularization (15). In a canine model of sustained flow

		Sestamibi		
		Normal	Mild-Moderate Defect	Severe Defect
Redistribution Thallium-201	Normal	412	88	21
	Mild-Moderate Defect	56	193	90
	Severe Defect	1	23	172

Agreement = 74% $K = .59$

FIGURE 5. Concordance between regional ^{201}Tl activity on redistribution images and sestamibi activity. Concordance in estimating the degree of tracer uptake was observed in 74% of segments ($k = 0.59$).

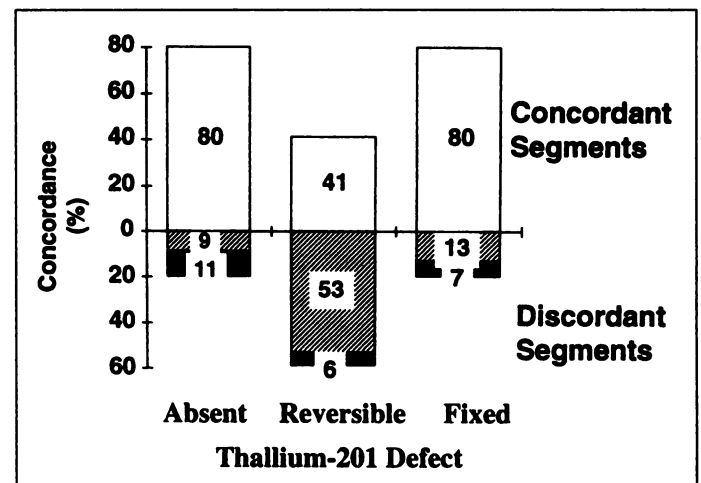
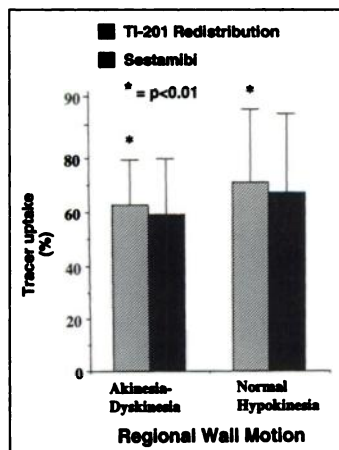


FIGURE 6. Bar graph showing percentage of matched segments with concordant (open bars) or discordant degree of tracer uptake (thallium-201 > sestamibi = hatched bars; sestamibi > thallium-201 = closed bars) in matched myocardial segments, according to the rest-redistribution ^{201}Tl pattern.

FIGURE 7. Bar graph showing the uptake of thallium-201 (TI-201, hatched bars) on redistribution images and of sestamibi (closed bars) in segments with akinesia and dyskinesia as well as segments with preserved wall motion (normal wall motion or hypokinesia). In both conditions sestamibi uptake was significantly lower than redistribution thallium-201 uptake.



reduction and severe systolic dysfunction, resting sestamibi distribution was found on average 5% less than redistribution ^{201}Tl uptake by Sansoy et al. On the contrary, the uptake of the two tracers was comparable in dogs with subendocardial infarction and persistent low flow as well as in dogs with extensive infarction (28).

Results of This Study

This study indicates that the quantified sestamibi activity 1 hr after resting injection parallels ^{201}Tl activity only in regions with normal ^{201}Tl uptake or in segments showing fixed defects. On the contrary, a lower sestamibi uptake was observed in segments with reversible ^{201}Tl defects, whether with preserved or reduced wall motion. Although there was a limited difference in the number of segments with severely reduced sestamibi or ^{201}Tl uptake (8% of the total segments), the global disagreement in segmental tracer uptake was 26% (Fig. 5). Our findings differ from those reported by Udelson et al. in humans (15). Technical differences between the two studies may account for some of these discrepancies. In Udelson et al.'s study, a same-day imaging protocol was used and sestamibi images were acquired after ^{201}Tl images. Thus, it is possible that some ^{201}Tl activity could have spilled over into the $^{99\text{m}}\text{Tc}$ window, thereby increasing the sestamibi counts. Moreover, only 8 mCi $^{99\text{m}}\text{Tc}$ sestamibi were injected: in other words, one-third of the dose used in our study, despite a similar image acquisition time. Even small ^{201}Tl spillover into the $^{99\text{m}}\text{Tc}$ window could increase sestamibi activity in the presence of a reduced count density. Although low ^{201}Tl spillover into $^{99\text{m}}\text{Tc}$ sestamibi images was recently found in patients undergoing same-day resting ^{201}Tl (2 mCi) and exercise sestamibi (40 mCi) imaging (29), we know no of available data with different imaging protocols.

Sestamibi and Myocardial Viability

Underestimation of residual myocardial viability through the use of resting sestamibi imaging in comparison to rest or 24-hr ^{201}Tl redistribution images (10,13,14) or metabolic [^{18}F]deoxyglucose imaging (11,12) has been reported. We recently reported that in the presence of hibernating myocardium after acute infarction, sestamibi may underestimate the amount of persistently dysfunctioning but still viable myocardium (30). Critically reduced blood flow may become the major determinant of myocardial sestamibi uptake, and the assessment of residual viability may be flawed by the use of a tracer whose distribution is largely perfusion-dependent and that redistributes minimally (8,25). Indeed, changes in blood flow supply can influence the resting tracer distribution: a decreased resting sestamibi uptake is reversible after nitroglycerin administration in a sizable number of stable patients with healed myocardial

infarction (21). However, different results have been reported recently regarding the accuracy of sestamibi imaging in determining myocardial viability (30,31).

Few data are available on optimizing the sestamibi imaging protocol for predicting residual viability. Sestamibi tracer injection after nitroglycerin administration (21,32) as well as delayed imaging after sestamibi injection (10) have been proposed recently. Of interest, Dilsizian et al. (10) have reported that sestamibi uptake was reduced in 36% of myocardial segments viable during ^{201}Tl redistribution and [^{18}F]fluorodeoxyglucose imaging. However, additional 4-hr sestamibi redistribution imaging showed improved sestamibi uptake in 38% of discordant defects (10). At odds with this result, Villaneuva-Meyer et al. found no change in sestamibi defect size between images acquired 1 hr and 4 hr after tracer injection (33). Although some delayed sestamibi redistribution has been observed under certain experimental conditions (25,28), its degree seems minimal, of a lesser extent than ^{201}Tl and difficult to detect in vivo.

LIMITATIONS

Since we have no data regarding regional wall motion after coronary revascularization, it is unknown which of the two tracers would have more accurately predicted viability as defined by functional recovery. Furthermore, in this study, sestamibi injection was not preceded by nitroglycerin sublingual administration, although cardioactive drugs, including long-acting nitrates, were not withheld. We performed sestamibi imaging 60–90 min after tracer injection and we cannot assume that the distribution of sestamibi remained stable after injection over time. Further ad hoc studies are required to better elucidate which particular sestamibi imaging protocol can substantially improve the detection of residual myocardial viability.

ACKNOWLEDGMENT

We thank Rosemary Allpress, MA, for her invaluable editorial assistance.

REFERENCES

- Dilsizian V, Bonow RO. Current diagnostic techniques of assessing myocardial viability in patients with hibernating and stunned myocardium. *Circulation* 1993;87:1–20.
- Ragosta M, Beller G. The noninvasive assessment of myocardial viability. *Clin Cardiol* 1993;16:531–538.
- Iskandrian A, Hakki AH, Kane SA, et al. Rest and redistribution Thallium-201 myocardial scintigraphy to predict improvement in left ventricular function after coronary arterial by-pass grafting. *Am J Cardiol* 1983;51:312–316.
- Bonow RO, Dilsizian V, Cuocolo A, Bacharach SL. Identification of viable myocardium in patients with chronic coronary artery disease and left ventricular dysfunction. Comparison of thallium scintigraphy with reinjection and PET imaging with [^{18}F]fluorodeoxyglucose. *Circulation* 1991;83:26–37.
- Ragosta M, Beller G, Watson D, Kaul S, Gimple L. Quantitative planar redistribution ^{201}Tl imaging in detection of myocardial viability and prediction of improvement in left ventricular function after coronary by-pass surgery in patients with severely depressed left ventricular function. *Circulation* 1993;87:1630–1641.
- Maddahi J, Schelbert H, Brunken R, Di Carli M. Role of thallium-201 and PET imaging in evaluation of myocardial viability and management of patients with coronary artery disease and left ventricular dysfunction. *J Nucl Med* 1994;35:707–715.
- Kiat H, Berman DS, Maddahi J, Yang LD, Van Train K, Rozanski A, Friedman J. Late reversibility of tomographic myocardial thallium defects: an accurate marker of myocardial viability. *J Am Coll Cardiol* 1988;12:1456–63.
- Okada R, Glover D, Gaffney T, Williams S. Myocardial kinetics of Tc-99m hexakis-2-methoxy-2-methylpropylisocyanide. *Circulation* 1988;77:491–498.
- Mousa SA, Cooney IM, Williams SI. Relationship between regional myocardial blood flow and the distribution of $^{99\text{m}}\text{Tc}$ -sestamibi in the presence of total coronary artery occlusion. *Am Heart J* 1990;119:842–847.
- Dilsizian V, Arrighi JA, Diiodati JG, et al. Myocardial viability in patients with chronic coronary artery disease. Comparison of $^{99\text{m}}\text{Tc}$ -sestamibi with thallium reinjection and [^{18}F]fluorodeoxyglucose. *Circulation* 1994;89:578–587.
- Altehoefer C, vom Dahl J, Biedermann M, et al. Significance of defect severity in technetium-99m-MIBI SPECT at rest to assess myocardial viability: comparison with fluorine-18-FDG PET. *J Nucl Med* 1994;35:569–574.

12. Sawada S, Allman K, Muzik O, et al. Positron emission tomography detects evidence of viability in rest technetium-99m-sestamibi defects. *J Am Coll Cardiol* 1994;23:92-98.
13. Cuocolo A, Pace L, Ricciardelli E, Chiariello M, Trimarco E, Salvatore M. Identification of viable myocardium in patients with chronic coronary artery disease: comparison of thallium-201 scintigraphy with reinjection and technetium-99m-methoxyisobutyl isonitrile. *J Nucl Med* 1992;33:505-511.
14. Marzullo P, Parodi O, Reisenhofer B, et al. Value of rest thallium-201/technetium-99m-sestamibi scans and dobutamine echocardiography for detecting myocardial viability. *Am J Cardiol* 1993;71:166-172.
15. Udelson JE, Coleman PS, Metherall J, et al. Predicting recovery of severe regional ventricular dysfunction. Comparison of resting scintigraphy with ²⁰¹Tl and ^{99m}Tc-sestamibi. *Circulation* 1994;89:252-256.
16. Van Train K, Maddahi J, Berman DS, et al. Quantitative analysis of tomographic stress thallium-201 myocardial scintigrams: a multicenter trial. *J Nucl Med* 1990;31:1168-1179.
17. Berger BC, Watson D, Burwell LR, et al. Redistribution of thallium at rest in patients with stable and unstable angina and the effect of coronary artery by-pass surgery. *Circulation* 1979;60:1114-1125.
18. Nichols AB, Brown C, Han J, Nickoloff EL, Esser PD. Effect of coronary stenotic lesions on regional myocardial blood flow at rest. *Circulation* 1986;74:746-757.
19. Rahimtoola S. The hibernating myocardium. *Am Heart J* 1989;117:211-221.
20. Parodi O, Sambucetti G, Roghi A, et al. Residual coronary reserve despite decreased resting blood flow in patients with critical coronary lesions. A study by technetium-99m human albumin microsphere myocardial scintigraphy. *Circulation* 1993;87:330-344.
21. Galli M, Marcassa C, Imperato A, et al. Effects of nitroglycerin by ^{99m}Tc-sestamibi tomoscintigraphy on resting regional myocardial hypoperfusion in stable patients with healed myocardial infarction. *Am J Cardiol* 1994;74:843-848.
22. Gewirtz H, Beller GA, Strauss HW, et al. Transient defects of resting thallium scans in patients with coronary artery disease. *Circulation* 1979;59:707-813.
23. Grunwald AM, Watson DD, Holzgrefe HH, Irving JF, Beller GA. Myocardial thallium-201 kinetics in normal and ischemic myocardium. *Circulation* 1981;64:610-618.
24. Budinger T, Pohost G, Bischoff P. Thallium-201 integral blood concentration over 2 hours explains persistent defects in patients with no evidence of MI by ECG [Abstract]. *Circulation* 1987;76(suppl IV):64.
25. Sinusas AJ, Bergin JD, Edwards NC, et al. Redistribution of ^{99m}Tc-sestamibi and ²⁰¹Tl in the presence of a severe coronary stenosis. *Circulation* 1994;89:2332-2341.
26. Rocco TP, Dilisizian V, Strauss WH, Boucher CA. Technetium-99m-isonitrile myocardial uptake at rest. 2. Relation to clinical markers of potential viability. *J Am Coll Cardiol* 1989;14:1678-1684.
27. Maurea S, Cuocolo A, Pace L, et al. Rest-injected thallium-201 redistribution and resting technetium-99m-methoxyisobutylisonitrile uptake in coronary artery disease: relation to the severity of coronary artery disease. *Eur J Nucl Med* 1993;20:502-510.
28. Sansoy W, Glover DK, Watson DD, et al. Comparison of thallium-201 and technetium-99m-sestamibi uptake and functional response to dobutamine for assessment of myocardial viability. *Circulation* 1995;92:994-1004.
29. Kiat H, Germano G, Van Train K, et al. Quantitative assessment of photon spillover in simultaneous rest Tl-201/stress Tc-99m-sestamibi dual isotope myocardial perfusion SPECT [Abstract]. *J Nucl Med* 1992;33:855.
30. Galli M, Marcassa C, Bolli R, et al. Spontaneous delayed recovery of perfusion and contraction after the first five weeks after anterior infarction. Evidence for the presence of hibernating myocardium in the infarcted area. *Circulation* 1994;90:1386-1397.
31. Medrano R, Wielbaeher D, Young JB, et al. Assessment of myocardial viability with technetium-99m-sestamibi in patients undergoing cardiac transplantation: a scintigraphic-pathologic study [Abstract]. *Circulation* 1992;86:1108.
32. Bisi G, Sciarra R, Santoro G, Fazzini PF. Rest Technetium-99m-sestamibi tomography in combination with short term administration of nitrates: feasibility and reliability for prediction of post-revascularization outcome of asynergic territories. *J Am Coll Cardiol* 1994;24:1282-1289.
33. Villanueva-Meyer J, Mena I, Diggles L, Narahara KA. Assessment of myocardial perfusion defect size after early and delayed SPECT imaging with technetium-99m-hexakis 2-methoxy isobutyl-isonitrile after stress. *J Nucl Med* 1993;34:187-192.

Dobutamine Thallium-201 Myocardial SPECT in Patients with Left Bundle Branch Block and Normal Coronary Arteries

Biray Caner, Celil Rezaghi, Ugur Uysal, Lale Tokgozoglu, Giray Kabakci, Nazenin Elahi, Sirri Kes, Tulin Aras, Omer Ugur and Coskun Bekdik

Departments of Nuclear Medicine and Cardiology, Hacettepe University Medical Faculty, Ankara, Turkey

Dobutamine is a positive inotropic and chronotropic agent and is being widely used as a pharmacologic stress agent in patients unable to achieve maximal dynamic exercise test. The purpose of the current study was to document the dobutamine induced false-positive septal defect in terms of its frequency and extent on ²⁰¹Tl myocardial SPECT in patients with left bundle branch block (LBBB). **Methods:** Twenty-five symptomatic patients with LBBB underwent dobutamine and redistribution ²⁰¹Tl myocardial SPECT studies. Coronary angiographies were also performed. Only those patients with normal coronaries (n = 19) were included in the study. For each study, tomograms were divided into 19 segments, and each segment was analyzed qualitatively as to presence and type of perfusion defect (reversible or fixed). In addition, septal perfusion was scored in each patient (1 = markedly, 2 = moderately reduced, 3 = normal uptake). **Results:** Sixteen of 19 patients (84.21%) had false-positive septal reversible perfusion defect, and the remaining 3 had normal images. Perfusion defects were confined to only the septum in 5 of 16 patients (31.25%), whereas a greater proportion of patients had septal defect extending to the contiguous myocardial areas, mainly to the anterior wall. Five of 16 patients with false-positive defects had a septal perfusion score of 1, while the remaining 11 had a score of 2. **Conclusion:** Dobutamine myocardial scintigraphy in patients with LBBB was misleading for the diagnosis of coronary artery disease, since up to 84.21% of patients had false-positive septal perfusion defects.

Key Words: thallium-201; myocardial scintigraphy; left bundle branch block; dobutamine

J Nucl Med 1997; 38:424-427

Dynamic exercise testing is the usual method of stress testing for myocardial perfusion scintigraphy. However, it is not ideal for detection of coronary artery disease in patients with left bundle branch block (LBBB) due to the high percentage of false-positive septal defects (1-3). For patients who are unable to exercise, alternative pharmacological stress agents to detect coronary artery disease have been developed. Dobutamine is one such agent with an accuracy and sensitivity similar to dynamic exercise or dipyridamole (4-7).

As a positive inotropic and chronotropic agent, dobutamine produces similar physiologic effects as exercise. Therefore, it is theoretically possible that dobutamine can induce false-positive septal abnormalities in patients with LBBB. This study was designed to determine the frequency of dobutamine-induced false-positive septal defects and the extent of such defects in patients with LBBB and normal coronary arteriograms.

MATERIALS AND METHODS

Patients

We studied 25 consecutive patients with LBBB and chest pain who were referred for dobutamine thallium myocardial perfusion scintigraphy followed by cardiac catheterization. Informed written

Received Feb. 20, 1996; revision accepted Jul. 3, 1996.

For correspondence or reprints contact: Biray Caner, MD, Department of Nuclear Medicine, Hacettepe University Medical Faculty, Ankara, Turkey 06100.