
Gallium-67 Uptake by a Benign Adrenocortical Adenoma

Jeffrey A. Jackson, L. Gill Naul, John L. Montgomery, William R. Carpentier, and John W. Roberts

Departments of Medicine, Radiology and Surgery, Scott and White Clinic, Scott and White Memorial Hospital, Scott, Sherwood and Brindley Foundation, Texas A&M University College of Medicine

A 55-yr-old man presented with an atypical relapsing meningitis and was found to have intense unilateral adrenal uptake by ^{67}Ga imaging. Computed tomography showed a 4-cm right adrenal mass which was hypointense on the T1-weighted images and mildly hyperintense on the T2-weighted images of a magnetic resonance (MR) scan. At surgery, a coincidental benign adrenocortical adenoma was found. Because ^{67}Ga uptake is usually associated with inflammatory or malignant lesions and malignant adrenal lesions are hyperintense on T2-weighted MR images, these findings contributed to diagnostic uncertainty in this patient. Thus, a nonhyperfunctional adrenocortical adenoma may be associated with abnormal ^{67}Ga uptake and atypical MR findings.

J Nucl Med 29:1451-1453, 1988

Gallium-67 (^{67}Ga) citrate imaging has been used primarily to detect inflammatory (1-3) or malignant (1,3,4) lesions. We describe a patient who had abnormal adrenal uptake of ^{67}Ga which caused some diagnostic uncertainty in the setting of an atypical relapsing meningitis. Ultimately this patient, a coincidental benign adrenocortical adenoma was demonstrated by adrenalectomy. Although gallium uptake occasionally occurs in benign neoplasms and benign nonfunctional adrenal adenomas are common with a reported incidence at autopsy from 1.4% to 8.7% (5), to our knowledge, ^{67}Ga uptake by a benign adrenocortical adenoma has not previously been reported.

CASE REPORT

A 55-yr-old male physician presented with headache, myalgias, fever, and mild cerebrospinal fluid (CSF) pleocytosis. A course of doxycycline was prescribed but 2 wk later, similar symptoms recurred and CSF pleocytosis was again detected. Lack of improvement necessitated hospitalization and parenteral treatment with doxycycline and ceftriazone was given. All CSF studies and cultures were negative, as were multiple serologic tests including febrile agglutinins, fungal, syphilis, rickettsial, viral encephalitis, Lyme agent, Colorado tick fever,

and toxoplasmosis titers. Gallium-67 imaging was performed to exclude an occult infective source. Whole-body images were obtained 48 hr following the intravenous administration of 5.2 mCi [^{67}Ga]citrate.

Intense uptake in the region of the right adrenal gland was visualized (Fig. 1). Computed tomography showed a 4-cm, well-circumscribed, low-density right adrenal mass (Fig. 2)

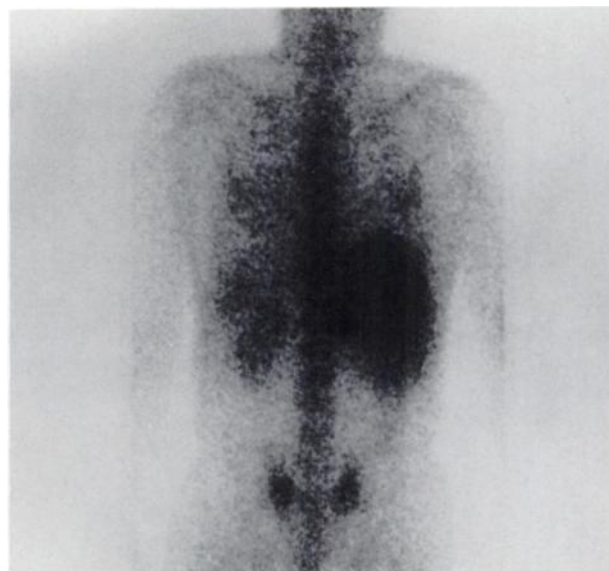


FIGURE 1
Increased focal activity (arrow) is identified in the region of the right adrenal gland on this posterior ^{67}Ga image.

Received Jan. 11, 1988; revision accepted Apr. 19, 1988.
For reprints contact: L. Gill Naul, MD, Dept. of Radiology, Scott and White Clinic, 2401 South 31st St., Temple, TX 76508.

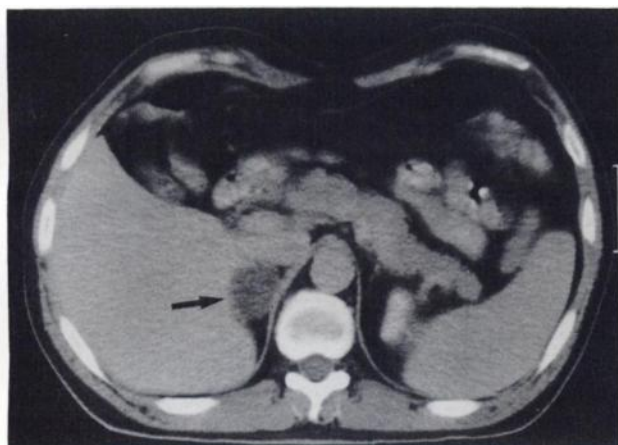


FIGURE 2
Contrast-enhanced CT scan shows low density right adrenal gland mass (arrow).

that did not enhance significantly with i.v. contrast. Magnetic resonance (MR) imaging performed on a superconducting magnet operating at 1.0 Tesla showed the adrenal mass to be hypointense on T1-weighted images and hyperintense on T2-weighted images (Fig. 3) with a signal intensity ratio of adrenal mass to liver of 1.9. All MR images were obtained using a spin-echo pulse sequence. A repetition time (TR) of 0.7 sec and an echo time (TE) of 16 msec were used for the T1-weighted images. The T2-weighted images were obtained using a multi-echo sequence with a TR of 2.5 sec and TE of 30 msec and 80 msec. Twenty-four-hour urinary cortisol was mildly elevated (117 μg ; normal 30–90) and was attributed to stress; the patient had no suggestive cushingnoid features. Urinary catecholamine metabolite excretion was normal. CT-directed needle biopsy from the periphery of the mass showed a few fragments of benign-appearing adrenocortical tissue and at adrenalectomy, a yellow benign adrenocortical adenoma was found. No pathologic evidence of necrosis within the adenoma was present. Postoperative recovery was unremarkable and subsequent serum cortisol determinations were normal. The patient returned to work after complete recovery from the aseptic meningitis.

DISCUSSION

The finding of an adrenal mass with intense ^{67}Ga uptake raised considerable clinical concern in the setting of our patient's atypical relapsing meningitis. Diagnostic considerations included fungal or other granulomatous diseases or malignancy such as lymphoma or carcinoma which could cause both the meningeal and adrenal manifestations. The hyperintensity of the mass on the T2-weighted MR images added further concern because benign cortical adenomas are typically hypointense relative to the liver on such images (6). In this patient, the benign adrenocortical adenoma was coincidental to the aseptic meningitis. The lack of post-operative cortisol suppression supported the clinical impression that the adenoma was not hyperfunctional, although preoperative dexamethasone suppression testing was not performed.

Gallium-67 uptake by adrenal glands has been most frequently described in childhood malignancies, particularly neuroblastomas (3). One case of malignant pheochromocytoma with ^{67}Ga uptake has been reported (7). Bilateral adrenal ^{67}Ga uptake has also been observed following ACTH treatment of opsoclonus-myoclonus syndrome in a child (8). One report of simultaneous benign cortical adenoma and metastatic carcinoma within the same adrenal gland showed uptake of radiocholesterol but not of ^{67}Ga by the adenoma (9).

The problem of the incidentally discovered adrenal mass has been reviewed previously (5). Generally, we recommend surgical excision for lesions >4 cm to 6 cm. Adrenocortical imaging with radiocholesterol may be useful to differentiate benign adrenal adenomas that take up the radionuclide from adrenal carcinomas that do not (10). This report demonstrates that ^{67}Ga and relative hyperintensity on T2-weighted MR images may occur in benign adrenocortical adenomas.

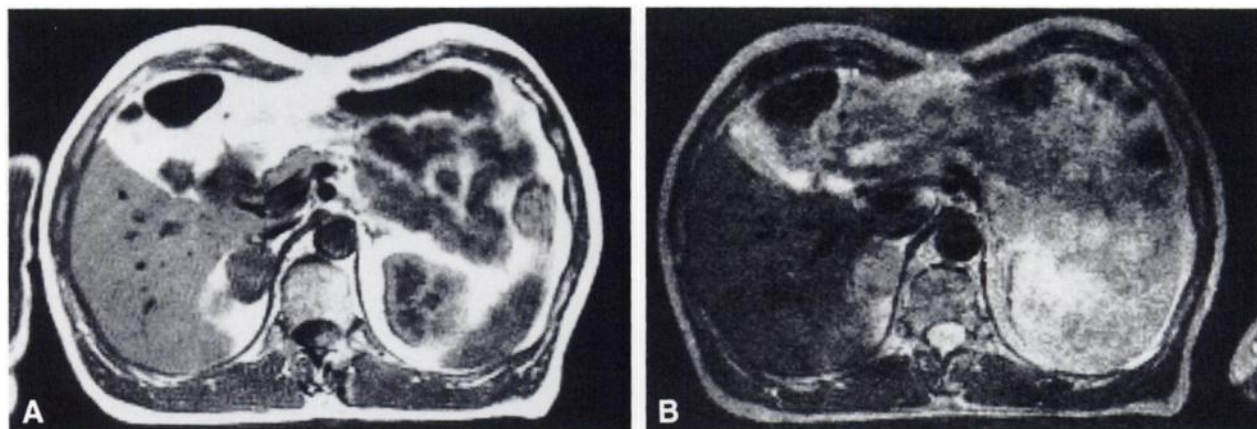


FIGURE 3
MR scan. A: T1-weighted image shows the adrenal mass to be of low signal intensity. B: Adrenal mass is hyperintense relative to the liver on this T2-weighted image.

REFERENCES

1. Lavender JP, Lowe J, Barker JR, et al. Gallium 67 citrate scanning in neoplastic and inflammatory lesions. *Br J Radiol* 1971; 44:361-366.
2. Littenberg RL, Taketa RM, Alazraki NP, Halpern SE, Ashburn WL. Gallium-67 for localization of septic lesions. *Ann Intern Med* 1973; 79:403-406.
3. Handmaker H, O'Mara RE. Gallium imaging in pediatrics. *J Nucl Med* 1977; 18:1057-1063.
4. Edwards CL, Hayes RL. Scanning malignant neoplasms with gallium 67. *JAMA* 1970; 212:1182-1190.
5. Copeland PM. The incidentally discovered adrenal mass. *Ann Intern Med* 1983; 98:940-945.
6. Glazer GM, Woolsey EJ, Borrello J, et al. Adrenal tissue characterization using MR imaging. *Radiology* 1986; 158:73-79.
7. Dawson J, Harding LK. Pheochromocytoma presenting as pyrexias of undetermined origin: diagnosis using gallium-67. *Br Med J* 1982; 284:1164.
8. Gumbinas M, Gratz ES, Johnston GS, et al. Positive gallium scan in the syndrome of opsoclonus-myoclonus treated with adrenocorticotrophic hormone. *Cancer* 1984; 54:815-816.
9. Hoshi H, Jinnouchi S, Ono S, et al. Scintigraphic demonstration of coexisting adenoma and metastasis of the adrenal gland in a patient with bronchogenic carcinoma. *Clin Nucl Med* 1984; 9:717-718.
10. Rizza RA, Wahner HW, Spelsberg TC, et al. Visualization of nonfunctional adrenal adenomas with iodocholesterol: possible relationship to subcellular distribution of tracer. *J Nucl Med* 1978; 19:458-463.