

PRELIMINARY NOTES

Intraoperative Lymph Scintigraphy during Radical Surgery for Cervical Cancer

Eduard Gitsch, Karl Philipp, and Norbert Pateisky

Universitäts-Frauenklinik, Wien, Austria

Intraoperative lymph scintigraphy during radical surgery for cervical cancer was developed in the course of a program covering three periods. During the last period technetium-99m antimony sulfide has been used to visualize pelvic lymph nodes. Surgery is done with a modified gamma camera serving as an operating table. This ensures intraoperative monitoring and greater thoroughness of lymphadenectomy. The introduction of the technique has improved the rate of total lymphadenectomies and has increased both the yields of involved nodes and the 3-yr survival rates.

J Nucl Med 25: 486–489, 1984

In patients with cervical carcinoma, regional lymph-node involvement is one of the decisive prognostic factors (1). Consequently, every surgeon will try to extirpate these lymph nodes as thoroughly as possible. Since some of them may be missed on visual inspection because they lie deep to vessels or ligaments, their intraoperative visualization has been attempted for years. However, vital staining of lymph nodes with carbon (2–4) or x-ray lymphography (5) has failed to produce the desired results and has therefore been discarded.

Lymph-node imaging using Tc-99m antimony sulfide provides an ideal tool for visualizing lymph nodes. A modified gamma camera serving as an operating table helps to monitor lymphadenectomy intraoperatively so that nodes can be removed more effectively (6).

This type of intraoperative lymph scintigraphy is the third step in a development program covering three periods, and has been in use since 1976. In the first two periods, regional pelvic lymph nodes were labeled with colloidal gold-198 (7). The dose was 100 μ Ci for each extremity. To identify labeled lymphatic tissue, a scanner was used in the first period (1970–72). In the second period (1973–76), lymph nodes were located with a gamma camera modified to serve as an operating table.

With this method of surgery, two problems are of interest: (a) whether interphalangeal injection of Tc-99m antimony sulfide can adequately visualize the nodes lying in the region of the obturator fossa; and (b) whether tracer uptake in carcinomatous nodes is adequate for detection with the gamma camera. Both of these problems, and the effects of more radical lymphadenectomy on the 3-yr survival rates, were investigated.

METHOD

On the evening before surgery, 500 μ Ci of Tc-99m antimony sulfide were injected between the second and third toes of both feet after applying a local anesthetic. The patient was then instructed to walk about to provide for adequate distribution in the lymphatics.

At surgery the patient was placed on a gamma camera that was modified to serve as an operating table (Fig. 1). The entire operative field should be arranged to lie on the collimator surface of the camera to ensure visualization of the lymph nodes in the lesser pelvis on the memory screen. The camera should "see" the entire pelvic region from the groins to the paralumbar nodes. Radical surgery for cervical carcinoma was done according to Latzko (8), with lymph-node removal constituting the first step of the operation. Using a computer coupled to the camera, summation images were obtained during the procedure to document the progress of lymphadenectomy. Any residual activity from nodes left in place

Received July 11, 1983; revision accepted Oct. 14, 1983.

For reprints contact: Norbert Pateisky, MD, Universitäts-Frauenklinik, Spitalgasse 23, A-1090 Wien, Austria.

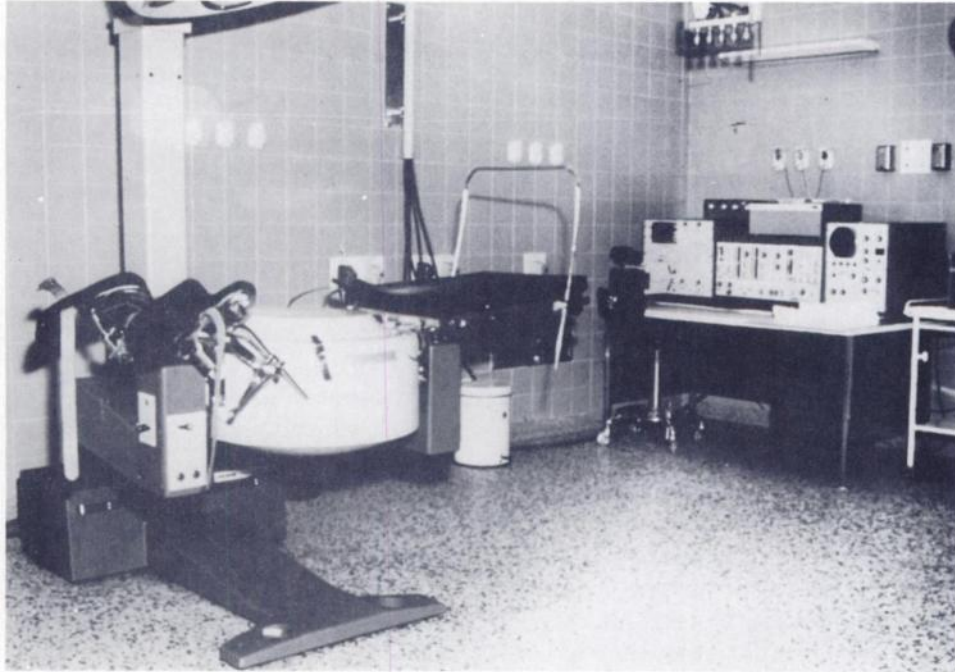


FIG. 1. Gamma-camera operating table with TV monitor.

during primary lymphadenectomy was located with a technetium-filled probe. This probe was moved to the site at which the activity emitted from it coincided with the residual activity displayed on the screen. The position of the probe thus indicated the location of those nodes that need to be removed from resection of the tumor mass.

MATERIAL AND RESULTS

To decide whether the deep obturator nodes and the carcinomatous nodes are visualized, the percentage uptake per gram of tissue was determined in five patients (Table 1). The activity recorded from the obturator nodes was found to be approximately the same as that from the superficial external and internal iliac nodes. Carcinomatous nodes accumulated somewhat less activity than normal nodes, but the difference was not significant statistically.

Between 1970 and 1979, 229 patients undergoing Latzko's radical operation for cervical cancer were

subjected to intraoperative lymph scintigraphy. In four of these, technical factors, i.e., electrocoagulation of a blood vessel during recording of the summation image, as inadequate visualization of the nodes in the operative field, ruled out an evaluation of the completeness of the procedure. Side effects and signs of intolerance were absent throughout. Local inflammation at the injection site occurred in a single case, but was rapidly cleared with appropriate treatment.

In the first period of the development program (Au-198 labeling and scanner) 61 females underwent surgery. Repeat scans at the end of the operation did not show any residual lymphatic tissue in 32 of them. This implies that total lymphadenectomy was successfully done in 53% of patients (Table 2).

The replacement of the scanner by a gamma camera improved the rate of total lymphadenectomy to 67% (65 of 97 cases). Since 1976 Tc-99m antimony sulfide has been used to label lymph nodes. By 1979, 71 females had undergone surgery, and 67 images were evaluated. Of

TABLE 1. PERCENTAGE UPTAKE OF THE INJECTED DOSE PER GRAM TISSUE

Lymph nodes	No.	Normal lymph nodes, percentage uptake mean \pm s.d.		Positive lymph nodes, percentage uptake mean \pm s.d.	
		No.		No.	
External iliac	8/10	0.42 \pm 0.22	2/10	0.28 \pm 0.06	
Internal iliac	10/10	0.37 \pm 0.24	—	—	
Obturator	5/10	0.35 \pm 0.17	5/10	0.24 \pm 0.10	
Rosenmüller's	9/10	0.45 \pm 0.24	1/10	0.34	

TABLE 2. RATE OF TOTAL LYMPHADENECTOMIES AND 3-yr SURVIVAL RATE DURING THE TWO PERIODS OF THE PROGRAM DEVELOPMENT FOR RADIONUCLIDE-ASSISTED RADICAL SURGERY OF CERVICAL CANCER

Program development	Radiocolloid	Total lymphadenectomy as assessed by imaging		Alive 3 yr	
		Patients	Percent	Patients	Percent
Period I 1970-1972	Au-198	32/61	53	46/61	75
Period II 1972-1976	Au-198	65/97	67	82/97	84
Period III 1976-1979	Tc-99m Sb ₂ S ₃	59/67	88	59/67	88

these, 59 (88%) were rated as total lymphadenectomies.

In the course of the three periods of our development program the distribution of clinical tumor stages has been more or less the same, with only minor shifts towards Stage I tumors without nodal involvement (Table 3). Postoperative radiotherapy was confined to patients with Stage II tumors and nodal involvement. Patients with Stage Ib tumors did not undergo adjuvant treatment.

The increase in the rate of complete lymphadenectomies was found to be associated with an improvement of the 3-yr survival rate. During the first period under review, with complete lymphadenectomy in 53% of cases, 46 of 61 patients (75%) were still alive after 3 yr. In the second period the 3-yr survival rate increased to 84%. Of the 67 patients undergoing surgery during the third period, 59 were alive after 3 yr, equivalent to a 3-yr survival rate of 88% (Table 2).

DISCUSSION

On account of their particle size, interstitially administered colloidal and other substances with a molecular weight in excess of 20,000 cannot pass the capillary walls. Rather they enter the lymphatics and are removed by lymphatic drainage. Through the afferent vessels they are transported to the marginal sinuses of the regional lymph nodes and are stored there in the reticulum. When these colloidal substances are labeled with a gamma-emitting radionuclide, they can be used for lymphatic studies after subcutaneous injection. Ac-

ording to zum Winkel (9), the substances should have the following properties to be suitable for lymph-node imaging: (a) they should be injectable subcutaneously; (b) they should be removed rapidly from the injection site; (c) they should deliver a low radiation dose to the patient; (d) they should be transported exclusively through the lymphatics; and (e) they should accumulate in several downstream lymph nodes. Tc-99m antimony sulfide can be regarded as an ideal substance for lymph scintigraphy.

During use of Tc-99m antimony sulfide, the liver constitutes the critically sensitive organ (10). With an injected dose of 500 μ Ci, the radiation dose to the liver is 150 mrad. The dose delivered to the lymphatics is around 500 mrad, which can be tolerated in view of the seriousness of the patient's basic disease.

Ever since lymphadenectomy has become mandatory in the treatment of cervical cancer, attempts have been made to increase its thoroughness (11-13). These necessitated preoperative labeling of lymph nodes to facilitate an evaluation of the extent of the procedure. Intraoperative lymph scintigraphy and the use of a modified gamma camera serving as an operating table constitute ideal tools for this purpose. They ensure that lymph-node removal can be monitored throughout surgery and that the operation can be extended to the point at which all lymph nodes are removed from the operative field. Concerns about the absence of staining in the deep obturator nodes after interphalangeal radionuclide application proved to be unfounded. Activity assays of the removed nodes with a scaler showed activity to be present in all nodes irrespective of tumor.

TABLE 3. TUMOR STAGE AND LYMPH-NODE INVOLVEMENT IN THE THREE PERIODS OF THE PROGRAM FOR DEVELOPMENT FOR RADIONUCLIDE-ASSISTED RADICAL SURGERY OF CERVICAL CANCER

Program development	Tumor stage; Lymph-node involvement									
	I neg		I Pos				II neg		II pos	
	Patients	%	Patient	%	Patient	%	Patients	%		
Period I 1970-1972	30/61	51	7/61	11	12/61	20	11/61	18		
Period II 1972-1976	52/97	54	12/97	12	14/97	14	19/97	20		
Period III 1976-1979	47/71	66	9/71	13	8/71	11	7/41	10		

The increased rate of total lymphadenectomy documents that the effectiveness of lymph-node removal has been improved by the introduction of radionuclide-assisted radical surgery. Before the technique of nodal labeling was used, lymphadenectomies were total in no more than 53% of cases. By contrast, the rate of total lymph-node removal was as high as 88% in the last period under review. No doubt this is attributable to the use of the gamma camera and the replacement of colloidal gold by technetium-antimony sulfide. The small particle size of colloidal technetium-antimony sulfide (3 to 5 nm) enhances lymph-node uptake of the substance and thus increases the accuracy of nodal staining. In addition, the 6-hr half-life of technetium compared with 2.7 days for colloidal gold is advantageous, as is the absence of the beta emission.

The increase in the number of total lymphadenectomies was associated with an increase of 3-yr survival rates. This appears to be attributable to the possibility of identifying and removing even minor lymph nodes, which may be missed on visual inspection. But the thoroughness of lymph-node removal also has therapeutic implications: under total lymphadenectomy a higher rate of nodal involvement was found (14). This, in turn, is of paramount importance for subsequent therapy, since lymph-node involvement is one of the factors to be considered when deciding for or against postoperative radiotherapy. The relatively high cost of the operating table and gamma-camera unit doubtless constitutes a disadvantage of the method. This could be overcome, however, by creating a central unit for radionuclide-assisted surgery, serving several surgical disciplines. After all, intraoperative lymph imaging is also being successfully used in the surgical treatment of testicular and breast cancer (15,16).

REFERENCES

1. DAVIDSON JW, VAN LIEROP MJ: Lymphography and prognosis in carcinoma of the cervix. *Am J Obstet Gynecol* 112:669-675, 1972
2. FRÖHLICH HH, SCHMIDT F, PISKAZECK K, KRIEG U: Farblymphographische ergebnisse mit einer kohlenstoff-lipoidol-suspension bei karzinomen des weiblichen genitalen. *Zbl Gynäkol* 102:374-379, 1980
3. LEITSMANN H, FICKWEILER J: Der Einsatz visköser farbstofflösungen zur vitalfärbung von lymphknoten. *Zbl Gynäkol* 98:1510, 1977
4. LUDVIK W: Vitalfärbung von Lymphknoten mit Kohlenstoff. *Acta Chir Aust* 3:1, 1971
5. KOLBENSTVEDT A, KOLSTAD P: Pelvic lymph node dissection under preoperative lymphographic control. *Gynecol Oncol* 2:39-59, 1974
6. GITSCH E, JANISCH H, TULZER H: Die radioisotopenradikaloperation des neoplasma colli uteri vom tyT III. *Geburtshilfe Frauenheilkd* 38:331-333, 1978
7. GITSCH E, JANISCH H, TULZER H: Die radikaloperation des carcinoma colli uteri mit radioisotopen vom typ. *Z Geburtsh Gynäk* 175:253-263, 1971
8. LATZKO W, SCHIFFMANN J: Klinisches und anatomisches zur radikaloperation des gebärmutterhalskrebses. *Zbl Gynäk* 34:689, 1919
9. ZUM WINKEL K: *Lymphologie mit Radionukliden*. Berlin, Hildegard Hoffmann, 1972, pp 22-27
10. Berufsverband deutscher nuklearmediziner e.V. mitteilungen. *Der Nuklearmediziner* 4:291-295, 1981
11. MEIGS JV: The Wertheim operation for carcinoma of the cervix. *Am J Obstet Gynecol* 49:542-553, 1945
12. OKABAYASHI H: Radical abdominal hysterectomy for cancer of the cervix uteri. *Surg Gynecol Obstet* 33:335-341, 1921
13. WERTHEIM E: Die erweiterte abdominale radikaloperation bei carcinoma colli uteri. Berlin, Urban u. Schwarzenberg, 1911, pp 214-219
14. TULZER H, KUPKA ST: Über den Unterschied der Effektivität der Lymphonodektomie bei der Radikaloperation des Kollumkarzinoms mit und ohne Drüsenbefall. *Gynäkol Rundsch* 17:141-148, 1977
15. GITSCH E, PHILIPP K, KUBISTA E: Die intraoperative Lymphszintigraphie bei der Radikaloperation des Mammakarzinomas. *Geburtshilfe Frauenheilkd* 43:112-115, 1983
16. KUBER W, LEODOLTER S: Radioisotopenlymphonodektomie bei malignen hodentumoren. *Urologe A* 19:25-31, 1980