

ALTERATION OF THE CEREBRAL BLOODFLOW STUDY DUE TO REFLUX IN INTERNAL JUGULAR VEINS

Jehuda J. Steinbach, Adel G. Mattar, and Dorsey T. Mahin

*Veterans Administration Hospital and State University of New York at Buffalo, Buffalo, New York,
and Richmond Memorial Hospital, Richmond, Virginia*

This paper considers abnormalities of flow patterns in the cervical vasculature due to varying degrees of jugular venous reflux, and their influence on cerebral bloodflow studies. Two commonly encountered patterns are described. In the first group, the abnormal flow study resulted from reflux of the activity in the left internal jugular vein. In the second group, the observed abnormality resulted from reflux of the activity in the left internal jugular vein, followed by flow into the contralateral jugular vein, most probably through the transverse and sigmoid sinuses.

The cerebral bloodflow study is a recognized adjunct to static scintigraphic examination of the brain (1). In many centers this study is performed routinely using rapid-sequential imaging following a bolus intravenous injection of ^{99m}Tc -sodium pertechnetate (2). Interpretation of the study is performed by observing the progression of the activity through the cervical vasculature and the cerebral hemispheres (3,4). The initial cervical flow is usually considered arterial, and alterations in this early phase are interpreted as arterial abnormalities. However, free passage of the administered radionuclide in the venous system en route to the heart is important in these studies. Venous obstruction to the administered bolus will delay—and may alter considerably—the arterial appearance of the tracer. In a routine clinical setting, the patency of the venous system is usually assumed since pretesting for this condition is impractical and probably not warranted. The recognition, however, of abnormal venous flow patterns in the neck during the early part of a cerebral bloodflow study is important to avoid misinterpretation of the findings.

Demonstration of varying degrees of reflux in the internal jugular veins, and of the consequences in a cerebral bloodflow study, is the basis for this report.

We studied ten patients (eight males and two females), their ages ranging from 45 to 78 years. Patients selected for the study exhibited various degrees of internal jugular reflux as shown on the cerebral bloodflow study, but none of them had exhibited any clinical signs or history that might suggest abnormality of the venous return from the upper extremities.

The study was performed using a Pho/Gamma III scintillation camera. A parallel-hole low-energy collimator was used for the cerebral bloodflow study and a medium-energy diverging collimator was used for the subclavian flow study.

All flow studies were performed following a rapid intravenous bolus injection (1 ml) of 10–15 mCi of ^{99m}Tc -sodium pertechnetate into the left antecubital vein with the patient in the sitting-up position. No saline flush was used. The arm was held in a stretched-out position, anterior and somewhat lateral to the patient. Polaroid films were exposed at 3-sec intervals following an initial delay determined by observing the persistence scope.

Cerebral bloodflow studies were routinely obtained in the anterior projection. The vertex projection was used in selected cases.

The subclavian flow study was performed in the anterior projection. The detector was positioned to optimize visualization of the left subclavian vein, both jugular veins, and the heart.

RESULTS

Abnormalities observed on the cerebral bloodflow study due to various degrees of venous reflux can be divided into two groups:

Received March 8, 1975; revision accepted Aug. 18, 1975.

For reprints contact: Jehuda J. Steinbach, Nuclear Medicine Service, Veterans Administration Hospital, 3495 Bailey Ave., Buffalo, N.Y. 14215.




FIG. 1. Anterior cerebral flow study in Group 1. Sequential views from left to right are at 6-9, 10-12, 13-15, 19-21, 29-31, and 32-35 sec. Reflux into left internal jugular vein is first seen at 6 sec; it persists to end of study at 38 sec. Column of activity terminates abruptly at midneck. Essentially normal arterial phase is seen after 18 sec.

Group 1. Reflux in the left internal jugular vein.

This condition is illustrated in Figs. 1 and 2. Following the intravenous administration of tracer, a column of activity was seen to rise in the left side of the neck, having a linear configuration with an abrupt termination. It appeared early, mostly within the first 3 sec, and persisted for the duration of the study. The intensity of the activity was much higher than would be expected if it were arterial. A typical arterial distribution pattern appeared late (19-21 sec), but the cerebral arteries were poorly delineated, most likely due to the marked delay in circulation time and dispersion of the bolus.

The corresponding left subclavian flow study (Fig. 2) showed a marked reflux into the left internal jugular vein. Delay in the passage of activity at the approximate region of the left innominate vein was clearly seen. Retention of activity in the left internal jugular and left subclavian veins persisted to the end of the study at 35 sec.

Group 2. Reflux in the left internal jugular vein with crossover to the right.

Figures 3 and 4 show anterior and vertex cerebral bloodflow studies in a Group 2 patient. Following tracer injection, the activity ascended in the left internal jugular vein, looped laterally, and then crossed to the contralateral side and descended in the right internal jugular. The appearance of activity in the arterial system was markedly delayed. Persistence in the left internal jugular vein extended to the end of the study at 42 sec. The vertex flow study (Fig. 4) showed the crossover from left to right to occur through the transverse and sigmoid sinuses. A delayed arterial phase was seen in the last view at 37 sec.

The corresponding left subclavian flow study (Fig. 5) showed marked obstruction to the flow at the region of the left innominate vein. As a consequence, reversed flow occurred in the left internal jugular vein, with crossover through the sigmoid and transverse sinuses as described above. Drainage into the right heart mainly occurred through the right internal jugular vein.

None of the above findings for either group could be reproduced in five normal subjects by varying the arm position or by inducing a Valsalva maneuver during the study.

DISCUSSION

The recognition that these patterns are venous rather than arterial is important to avoid misinterpretation of the cerebral bloodflow study. The estimated frequency of this phenomenon in our laboratory is 4 cases out of 1,000.

In differentiating venous reflux from arterial activity, the following points should be considered.

1. Venous reflux appears early—frequently within a few seconds after administration of the tracer.
2. The intensity of the activity due to venous

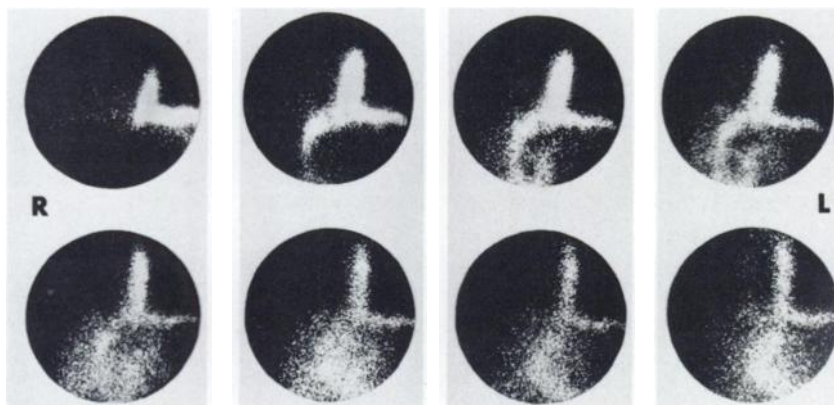


FIG. 2. Left subclavian flow study in Group 1. Sequential views are at 2-4, 5-6, 7-8, 9-10, 11-12, 13-14, 15-16, and 17-18 sec. Following initial delay of passage at innominate vein, activity is seen to proceed normally. Marked retention of tracer is still seen at left subclavian and left internal jugular veins at end of study (17-18 sec).

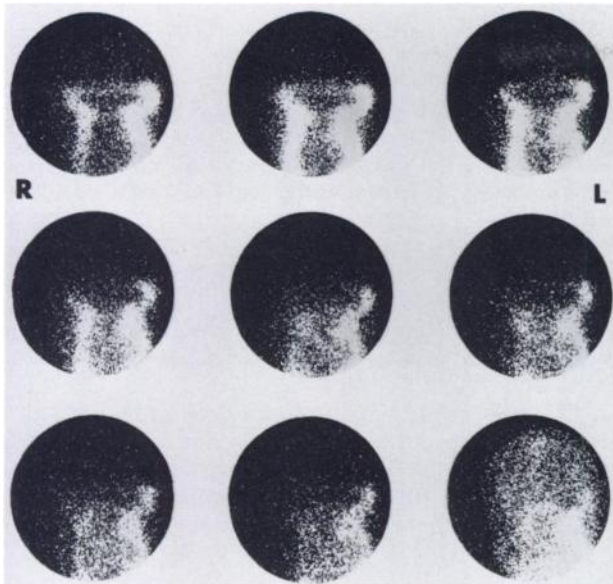


FIG. 3. Anterior cerebral flow study in Group 2. Sequential views are at 6-9, 10-12, 13-15, 16-18, 19-21, 22-24, 25-27, 28-30, and 40-42 sec. Reflux into left internal jugular vein is followed by lateral loop and horizontal crossover into contralateral side. Marked activity in left internal jugular vein is seen up to end of study at 42 sec. Arterial phase can be seen at 40-42 sec, and it appears symmetric.

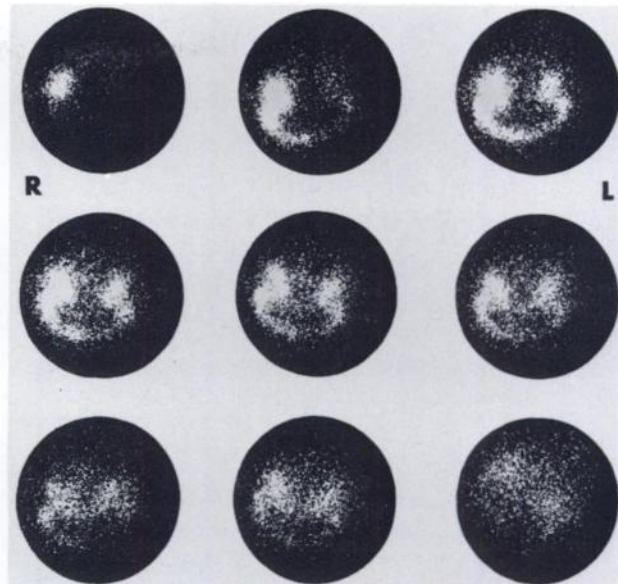


FIG. 4. Vertex cerebral flow study in Group 2. Sequential views are at 5-8, 9-11, 12-14, 15-17, 18-20, 21-23, 24-26, 27-29, and 35-37 sec. Ascending column of activity in left internal jugular vein is seen at 5-8 sec, at internal jugular bulb. Activity then crosses over through sigmoid and transverse sinuses into right internal jugular vein. Normal arterial phase is seen in last frame at 35-37 sec.

reflux is always much higher than would be anticipated in an arterial flow.

3. The pattern is typical when the radionuclide is seen rising on one side of the neck, either terminating abruptly or crossing over and descending on the opposite side.
4. The arterial phase is usually delayed.

We do not yet know the cause of the described finding. Obstruction and diversion of the venous flow at the region of the subclavian and innominate veins have been reported in several conditions, such as the thoracic outlet syndrome (5,6), primary venous obstruction of the upper extremities (7,8), aneurysmal dilatation of the superior vena cava (9,10), or infection and tumors (9). Recent case reports of simi-

lar abnormalities on the cerebral bloodflow study have suggested that this phenomenon may possibly be due to a Valsalva maneuver (11) or to mediastinal tumors (12). In all the cases of this abnormality that we have studied to date, however, no associated clinical findings were noted. None of the patients presented with symptoms of the thoracic outlet syndrome or symptoms that might suggest isolated venous occlusion and drainage abnormalities. In all cases the abnormality was an incidental finding during the cerebral bloodflow study. In addition, the abnormality was seen only when the bolus was administered in the left arm. A second injection into the right antecubital vein resulted in normal flow studies. Valsalva maneuvers on five normal subjects

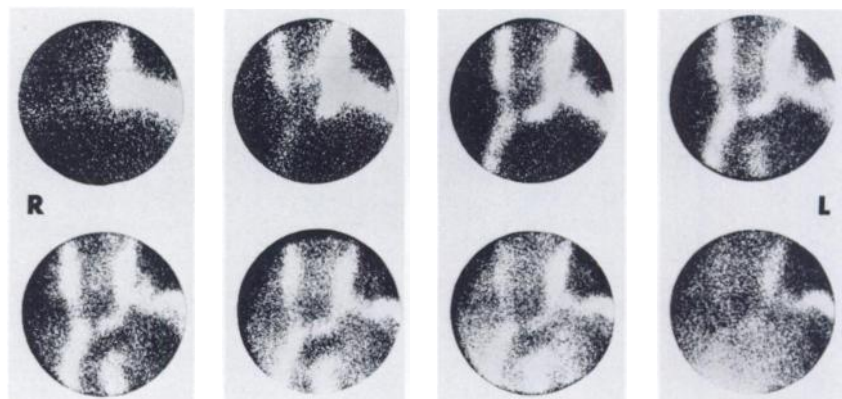


FIG. 5. Left subclavian flow study in Group 2. Sequential views are at 5-8, 12-14, 15-17, 18-20, 21-23, 24-26, 27-29, and 35-37 sec. Reflux into left internal jugular vein is seen at 5-8 sec. High-grade or possibly complete obstruction is shown at left innominate vein. Activity descends in right internal jugular vein at 11 sec and reaches right heart by 20 sec. Tracer retention at left subclavian and left internal jugular veins is seen to end of study at 37 sec.

failed to reproduce the previously described abnormalities.

Further studies are needed to elicit the mechanisms that may be responsible for these observations.

ACKNOWLEDGMENTS

The authors wish to thank Monte Blau for reviewing this manuscript and for his helpful comments. Expert secretarial assistance was rendered by Marianne G. Latchford.

REFERENCES

1. OLDENDORF WH: Clinical applications of brain blood flow studies. *Semin Nucl Med* 1: 107-119, 1971
2. OLDENDORF WH, KITANO M, SHIMIZU S: Evaluation of a simple technique for abrupt intravenous injection of radioisotope. *J Nucl Med* 6: 205-209, 1965
3. COWAN RJ, MAYNARD CD, MESCHAN I, et al: Value of the routine use of the cerebral dynamic radioisotope study. *Radiology* 107: 111-116, 1973
4. GRIEP RJ, WISE G, MARTY R: Detection of carotid artery obstruction by intravenous radionuclide angiography. *Radiology* 97: 311-316, 1970
5. LANG EK: Arteriography and venography in the assessment of thoracic outlet syndromes. *South Med J* 65: 129-136, 1972
6. ROOS DB, OWENS JC: Thoracic outlet syndrome. *Arch Surg* 93: 71-74, 1966
7. ROWEN M, DORSEY TJ, HEPPS SA: Primary venous obstruction of the upper extremity. *California Med* 118: 18-23, 1973
8. STEINBERG I: Angiographic features of primary venous obstruction of upper extremity. *Am J Roentgenol Radium Ther Nucl Med* 98: 388-396, 1966
9. OKAY NH, BRYK D: Collateral pathways in occlusion of the superior vena cava and its tributaries. *Radiology* 92: 1493-1498, 1969
10. GABRIELE AR, NORTH L, PIRCHER FJ, et al: Aneurysmal dilatation of the superior vena cava. *J Nucl Med* 13: 227-229, 1972
11. FRIEDMAN BH, LOVEGROVE FTA, WAGNER HN: An unusual variant in cerebral circulation studies. *J Nucl Med* 15: 363-364, 1974
12. PEART RA, DRIEDGER AA: Effect of obstructed mediastinal venous return on dynamic brain blood flow studies: Case report. *J Nucl Med* 16: 622-625, 1975

**TECHNOLOGIST SECTION
SOCIETY OF NUCLEAR MEDICINE
THIRD ANNUAL WINTER MEETING**

February 6-8, 1976

Chase Park Plaza Hotel

St. Louis, Missouri

Announcement

Three days of seminars, workshops, and exhibits on all aspects of nuclear medicine.

Continuing education certificates will be awarded.

For further information and registration forms contact:

Technologist Section, Society of Nuclear Medicine

475 Park Avenue South, New York, N.Y. 10016