

GLYCOPYRROLATE IN

^{99m}Tc-PERTECHNETATE BRAIN IMAGING

Richard A. Holmes and Colin N. Luth

Milwaukee County Medical Complex, Medical College of Wisconsin, Milwaukee, Wisconsin

Glycopyrrolate, a synthetic anticholinergic agent, was administered parenterally to two groups of patients referred for ^{99m}Tc-pertechnetate brain imaging to assess its ability to suppress pertechnetate uptake by the choroid plexus, oral mucosa, and salivary (parotid) glands. Pertechnetate activity was almost completely eliminated from the choroid plexus and mouth and appeared to be moderately reduced in the parotid gland. The drug can be given orally and may prove valuable in pertechnetate brain imaging.

Technetium-99m-pertechnetate is normally concentrated by the choroid plexus, salivary glands, and oral mucosa. Their uptake frequently interferes with the accurate interpretation of the brain image unless drugs such as perchlorate or atropine are administered to suppress their uptake. Of the two drugs, perchlorate has gained widest popularity and use because it has not been associated with negative side effects. The intent of this study is to determine the efficacy of glycopyrrolate, a synthetic anticholinergic drug, in suppressing pertechnetate uptake by these structures. Since glycopyrrolate is purported to have fewer side effects than atropine, its suppression of these structures would establish it as a possible alternate drug in pertechnetate brain imaging.

METHOD

Twenty patients referred for routine pertechnetate brain images were selected and divided into two equal groups. Group 1 received 0.2 mg of intravenous glycopyrrolate 20 min before the administration of 200 μ Ci/kg of intravenous ^{99m}Tc-pertechnetate. Group 2 patients received 0.2 mg of glycopyrrolate intramuscularly 20 min before the pertechnetate. Perchlorate was not given and the brain images were performed using either a dual 5-in. crystal rectilinear scanner or an Anger scintillation camera. Imaging

TABLE 1. ASSESSMENT OF RADIOACTIVE INTENSITY.

Injection	Time (min)	Radioactive intensity		
		Choroid plexus	Parotid gland	Oral
Intramuscular	20	< +	++	+
	120	< +	> ++	+++
Intravenous	20	< +	> +	+
	120	< +	> +	> ++

was begun at 20 min and again at 2 hr following the pertechnetate injection. Images were taken from the anterior, posterior, vertex, and both lateral views.

Three experienced nuclear medicine physicians graded the two lateral and vertex images independently for their radioactive intensity in the oral cavity area, parotid glands, and choroid plexus using a scale from 0 to + + + +.

Each patient was questioned about side effects to the glycopyrrolate during the early and late imaging. Patients with glaucoma, tachyarrhythmias, congestive heart failure, coronary insufficiency, cardio-spasm, pyloric stenosis, or prostatism were excluded from the study.

RESULTS

Table 1 is a compilation of observations assessing the radioactive intensities in the choroid plexus, parotid glands, and oral cavity area on the lateral and vertex brain image views. Images started 20 min after the pertechnetate injection showed practically no choroid plexus activity but definite, though proportionately lower, oral cavity uptake in both groups. In the parotid glands the pertechnetate activity

Received Dec. 12, 1974; revision accepted March 21, 1975.

For reprints contact: Richard A. Holmes, Div. of Nuclear Medicine, Milwaukee County Medical Complex, 8700 W. Wisconsin Ave., Milwaukee, Wis. 53226.

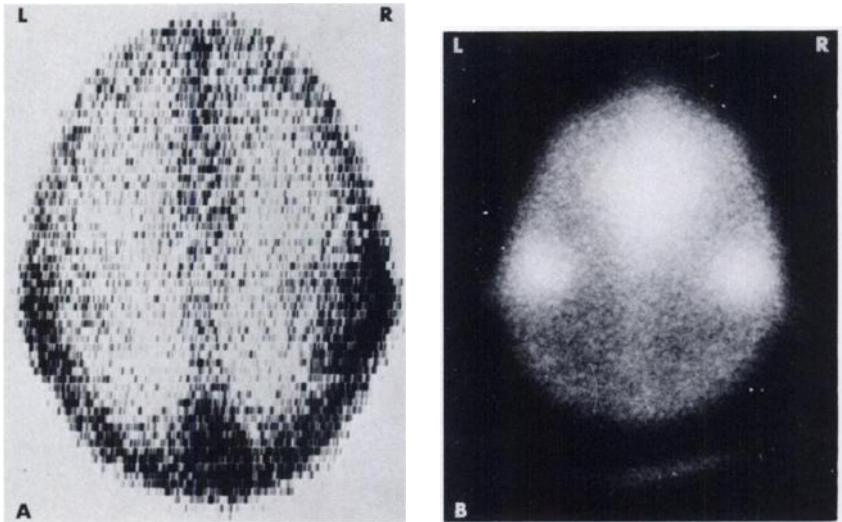


FIG. 1. (A) Pertechnetate vertex scan (20 min) following intramuscular glycopyrrolate showing minimal oral and moderate bilateral parotid gland radioactivity. (B) Pertechnetate vertex image (120 min) in same patient showing intense oral and increased parotid gland activity.

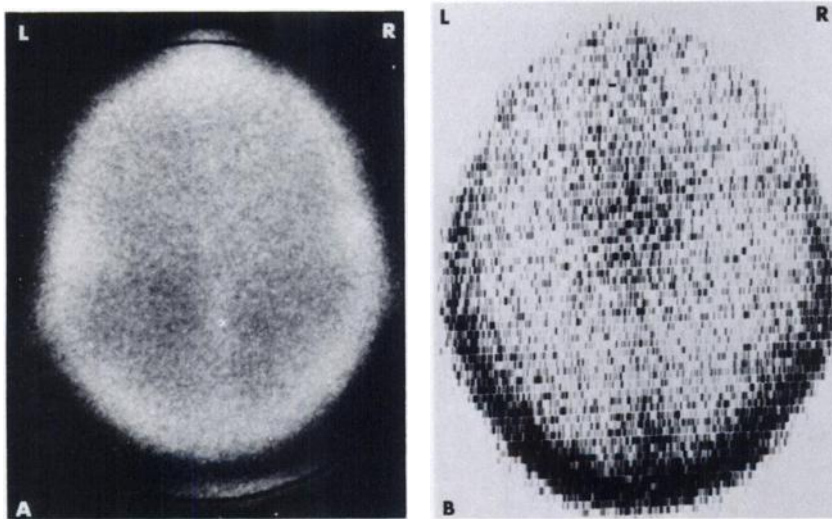


FIG. 2. (A) Pertechnetate vertex image (20 min) following intravenous glycopyrrolate showing minimal oral and parotid gland radioactivity. (B) Pertechnetate vertex scan (120 min) in same patient showing increased oral activity but no appreciable parotid gland activity.

showed at least ++ intensity in both groups. The relative absence of choroid plexus activity persisted on the 2-hr images with either method of glycopyrrolate administration. Oral cavity activity increased significantly on the 2-hr images but showed minimal or no increase in the parotid gland activity, particularly after the intravenous glycopyrrolate (Figs. 1 and 2).

Minimal side effects were encountered with parenteral glycopyrrolate and included dry mouth, increased pulse rate, and mydriasis (Table 2). None of the complaints were spontaneously volunteered by the patients.

DISCUSSION

When it became evident that the normal distribution of ^{99m}Tc -pertechnetate included uptake by the choroid plexus, salivary glands, and oral mucosa, the accuracy of interpreting brain images became suspect. Adequate visualization of the cerebral hemi-

spheres on the brain images was assured when drugs were administered that eliminated or reduced the uptake of ^{99m}Tc -pertechnetate by these structures. Perchlorate, either the potassium or sodium salt, is given by mouth in most nuclear medicine laboratories prior to the time of the pertechnetate administration (1,2). Perchlorate works by competitively inhibiting the uptake of pertechnetate by the choroid plexus and salivary glands causing it to be discharged into the cerebrospinal fluid and saliva. Atropine is more selective in its use and is usually given intravenously with the pertechnetate (3). Atropine is anticholinergic and blocks the neurogenic stimulus to the salivary glands preventing the concentration of pertechnetate. Its effect on choroid plexus uptake of pertechnetate is unknown.

Neither drug has been successful in completely eliminating pertechnetate concentration in each of the structures at their usual administered dosage. Attempts to enhance their effect by increasing their

TABLE 2. SIDE EFFECTS ENCOUNTERED WITH GLYCOPYRROLATE

Side effects	Intramuscular			Intravenous		
	Before	20 min	120 min	Before	20 min	120 min
Dry mouth	0	8 pt	8 pt	0	6 pt	7 pt
Blurred vision	0	0	0	0	1 pt	0
Dilated pupils	0	1 pt	3 pt	0	2 pt	5 pt
Urinary retention	0	0	0	0	0	0
Pulse/min	94	98	104	83	83	95
Nausea or vomiting	0	0	0	0	1 pt	0

dosage are probably not justified because of the non-specific nature of brain imaging and the possibility that they could, particularly the atropine, produce potentially dangerous or undesirable side effects.

To determine the effectiveness of higher dosage on pertechnetate suppression in these structures, we administered parenteral glycopyrrolate, a synthetic anticholinergic drug, to patients referred for pertechnetate brain images (4,5). Regardless of the mode of administration, the pertechnetate activity was completely eliminated from the choroid plexus and significantly reduced in the oral mucosa areas on the earlier images. Parotid gland activity was more difficult to assess but showed qualitative and consistent suppression. Side effects from the glycopyrrolate were minimal and abated in a reasonably short time.

Although the number of patients in this study is small, the preliminary results have encouraged us to use glycopyrrolate routinely in our brain imaging. Because of the need to delay the start of the pertechnetate brain imaging in spite of the effectiveness of the parenteral drug, we now administer the glycopyr-

rolate orally in a dose of 2.0 mg 15–20 min before the pertechnetate to prolong its effect.

ACKNOWLEDGMENT

Thanks are extended to John A. Emerick of the A. H. Robins Co. for providing us with the glycopyrrolate (Robinul®).

REFERENCES

1. WITCOFSKI RL, JANEWAY R, MAYNARD CD, et al: Visualization of the choroid plexus on the technetium ^{99m}brain scan: clinical significance and blocking by potassium perchlorate. *Arch Neurol* 16: 286–289, 1967
2. BARDFELD PA, HOLMES RA: Pertechnetate accumulation in the choroid plexus. *Am J Med Sci* 254: 542–548, 1967
3. HOLMES RA, HERRON CS, WAGNER HN: A modified vertex view in brain scanning. *Radiology* 88: 498–503, 1967
4. FRANKO BV, ALPHIN RS, WARD JW, et al: Pharmacodynamic evaluation of glycopyrrolate in animals. *Ann NY Acad Sci* 99: 131–149, 1962
5. SINCLAIR WP, SCHNEIR ES: Clinical evaluation of glycopyrrolate and atropine sulfate. *Am J Gastroenterol* 44: 62–65, 1965

NEW ENGLAND CHAPTER THE SOCIETY OF NUCLEAR MEDICINE ANNUAL MEETING

October 18-19, 1975

Colonnade Hotel
120 Huntington Avenue
Boston, Massachusetts

Further information may be obtained by contacting Kenneth A. McKusick, M.D., Department of Radiology, Division of Nuclear Medicine, Massachusetts General Hospital, Boston, Mass. 02114.