

IMPROVED DIAGNOSIS OF "NONDELINEATED" THYROID NODULES BY OBLIQUE SCINTILLATION SCANNING AND ECHOGRAPHY

Manfred Blum and Amy Beth Goldman

New York University Medical Center, New York, New York

The scan of the thyroid gland in oblique projections has enabled us to visualize 11 "cold" thyroid nodules which were not delineated on a traditional anterior view among 825 patients studied in a 2-yr period. Accurate localization of the nodule in the oblique projection facilitated accurate placement of the transducer for echography. The combination of the isotope imaging studies and ultrasound then permitted one to differentiate solid and cystic "cold" nodules. Diagnosis and choice of therapy are therefore enhanced by the addition of oblique views, when needed, and echography.

The addition of an oblique view of the ^{131}I scintiscan to the examination of patients with palpable thyroid lesions has demonstrated the position of 11 nonfunctioning nodules that were not detected on the routine anterior study. The precise localization of a nodule, which is "cold" to scintillation scanning, is needed to accurately employ echography in order to differentiate cystic and solid lesions. These two diagnostic techniques are of primary diagnostic importance.

A small number of palpable thyroid nodules in patients are detected clinically, but fail to be visualized on routine anterior scintillation scans. An erroneous negative scan report may result in these cases being dismissed as normal or thyroid echography can be inaccurate due to imprecise placement of the transducer. The addition of oblique ^{131}I scans to the workup of nonvisualized palpable thyroid masses has demonstrated 11 nodules not seen on anterior study. This has contributed significantly to the complete evaluation and optimal treatment of these patients.

MATERIALS AND METHODS

The problem of a palpable thyroid nodule that was not detected by a scintillation scan in the con-

ventional anterior projection arose in 11 of 825 patients studied in the Division of Nuclear Medicine of New York University Hospital during a 24-month period. In one of these cases, the anterior view alone erroneously led one to infer that the nodule was "hot."

Ten of the 11 studies were performed 24 hr after oral administration of 50–100 μCi of ^{131}I . A Picker Magna Scanner III equipped with a high-resolution 3-in. focusing collimator was used. One scan was performed 30 min after intravenous administration of $^{99\text{m}}\text{TcO}_4$, using the same scanner and collimator.

After the anterior scan had been completed and was deemed inconclusive, a scan in the oblique projections was done at once using the same equipment. The degree and direction of obliquity was determined for each subject, depending on the position of the nodule. Generally, 45-deg oblique studies were done. The degree of obliquity was designed both to separate the superimposed functioning tissue from the nodule and to allow proper positioning of the collimator without interference from the shoulder. In some patients these considerations necessitated doing several scans in varying degrees of obliquity.

The patients were positioned with a foam rubber wedge or pillows. Accuracy and reproducibility of the scans depend on precise palpation by an experienced physician, and by drawing the projection of the palpable nodule on the skin while the patient is lying in the scanning position. The nodule is also transposed onto the film in this position. For the latter purpose the collimator is equipped with a device for making the "teledeltos" paper and film and a light source that projects a narrow beam of light corresponding to the center of the collimator onto the patient's neck.

Received Oct. 15, 1974; revision accepted Feb. 26, 1975.

For reprints contact: Manfred Blum, New York University Medical Center, University Hospital, 560 First Ave., New York, N.Y. 10016.

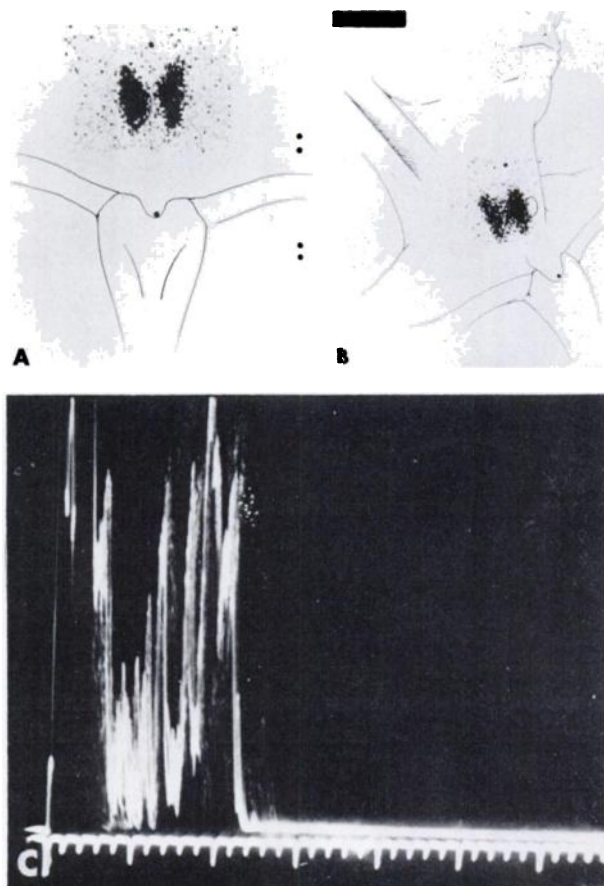


FIG. 1. (A) Anterior scan failed to demonstrate abnormality in area of palpable nodule. (B) Oblique scan showed palpable nodule to be anterior and peripheral in right lobe. (C) Echography demonstrated dense echoes compatible with solid mass.

In addition to marking the nodule, four lines of reference were transcribed onto the scan in the scanning position to facilitate anatomic correlation: (A) the mandible, (B) the thyroid cartilage, (C) the contralateral sternocleidomastoid muscle, and (D) the manubrium and clavicles. It is stressed that accurate drawing of these landmarks and the palpable nodule in the precise position of scanning are both critical. The patient must maintain the position without moving throughout the study.

RESULTS

In the past 24 months, 11 of 825 patients with palpable thyroid nodules had anterior scans which failed to localize the pathologic tissue, an incidence of 1.3%. In each of these cases an additional scan performed in the oblique projection disclosed the position of the nonfunctioning nodule with respect to the normal thyroid tissue, e.g., anterior versus posterior. The lesions in five of these patients were located in an anterolateral position. Four were on the anterior surface of the gland close to the midline. Two were placed posterolaterally.

A-mode echography was performed on ten of these 11 patients. In four there were dense homogeneous echoes compatible with solid lesions (Fig. 1). Three of these four patients were treated surgically. The pathologic diagnoses were colloid goiter, follicular adenoma, and nodular thyroid. The fourth subject was thought clinically to have a multinodular goiter, was treated with thyroid hormone suppressive therapy, and followed clinically. Four had sonolucent zones that corresponded in diameter to that of the palpable nodule indicative of a cystic lesion (Fig. 2). One patient with a sonolucent lesion did have the lesion removed surgically and pathology confirmed it to be a thin-walled benign cyst. Two others had a history of sudden onset of severe pain in the neck which radiated to the ipsilateral ear, supporting an impression of hemorrhagic cyst. They were treated with suppressive therapy and the masses resolved. The fourth patient, whose studies indicated a thyroid cyst, was also given drug therapy. The last two subjects showed a mixed sonographic pattern of echo-free zones interspersed with echo spikes that was interpreted as cystic or hemorrhagic degeneration of solid tissue. One underwent surgery and had a nodular thyroid on pathologic examination; the other was given suppressive therapy. This patient's nodule has shrunk but has not disappeared.

DISCUSSION

One of the primary purposes of the thyroid scan is the differentiation of the functioning (or "hot") and nonfunctioning (or "cold") nodule. The accuracy of thyroid imaging in evaluating a mass lesion depends on the ability of the clinician to palpate the area of abnormality and to correlate it with the corresponding area on the scan. In a small number of patients the examiner can detect a palpable distortion of thyroid architecture, but the routine anterior scan is normal. The problem of contradictory clinical and scan findings can be related to geometric factors; a posteriorly placed nonfunctioning area may be obscured by surrounding radioactivity or a superficial "cold" area may be missed due to the detection of the functioning tissue behind it. The visualization of a nonfunctioning nodule depends on a 20% decrease in radioactivity of all thyroid tissue in the plane of the nodule, i.e. "the function of the nodule plus that of all the tissue anterior or posterior to it" (1).

Although thyroid scanning is primarily a procedure for evaluating morphologic abnormalities, it is one of the few imaging techniques that routinely relies on a single projection. This severe geometric limitation has been recognized by several authors (1-7). Miller, et al (1) have even formally termed

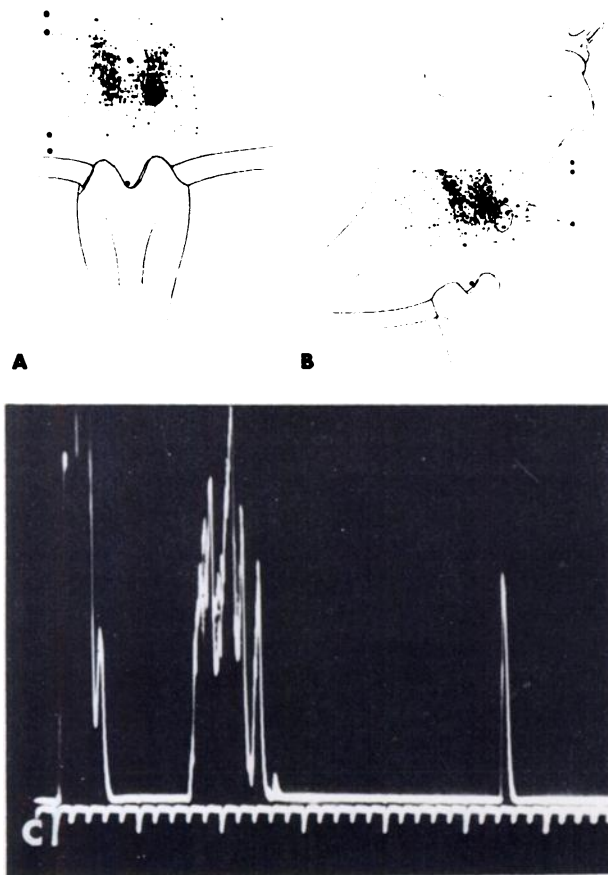


FIG. 2. (A) Anterior scan shows heterogeneous uptake of isotope; however, nodule marked on left lobe is not clearly delineated. Indeed, there may even be some increased uptake in this region. Treatment with triiodothyronine caused normal suppression, ruling out an autonomous nodule. (B) Oblique view demonstrates area of no radioactivity corresponding to palpable nodule which is anterio-lateral to rest of lobe. Therefore, nodule did not correspond to coincidental area of increased radioisotope activity on anterior projection and routine anterior scan was misleading. (C) A-mode echogram shows sonolucent zone corresponding to nodule proven cystic at surgery. Patient had nodular thyroid. More active region of lower pole of left lobe behind nodule was hypertrophic.

those masses which are palpated but not seen on the anterior scan as “nondelineated nodules.” In a recent review article correlating anterior thyroid scans with surgical pathologic findings, only 88% of solitary nodules were detected preoperatively despite efforts to increase resolution with the use of ^{99m}Tc , a pinhole collimator, and two to three times magnification (7).

Techniques of performing multiple projections to locate accurately palpable thyroid masses are infrequently used. One possible reason is the inadequacy of the lateral view due to the superimposition of the contralateral lobe and the interference of the shoulder in positioning the collimator (4,6). References to oblique scans are few and usually imply that the anterior view suffices except in unusual circumstances (2,8). Maynard's text (8) also suggests that nodules

that are not visualized on the anterior scan have decreased incidence of malignancy—which is difficult to justify. The use of both oblique views was also cited as an advantage in employing ^{99m}Tc scans with the scintillation camera in order to obtain stereoscopic views and “occasionally” to detect indentations on active tissue that were not previously perceived. The value of the oblique view in eliminating the category of “nondelineated nodules” has been recognized (5).

The accurate localization of a “nonvisualized” mass with oblique views is important to confirm palpation findings. Without it one may reason that if one feels a nodule but does not observe increased activity associated with it, then the nodule probably is “cold”, but the oblique scan allows one to make the appropriate observation.

With the advent of thyroid echography to complement the scintillation scan of the thyroid, greater diagnostic accuracy has become possible. By eliminating those small cystic lesions which are rarely malignant (9), one can avoid some thyroid operations. The accurate localization of “nonvisualized” mass with oblique views becomes important as an additional aid in placing the ultrasound transducer. When the thyroid scintiscan is done in several projections in combination with ultrasonography, one may locate a small solitary thyroid nodule accurately and also ascertain its cystic or solid nature. This may have profound diagnostic, therapeutic, and prognostic significance.

REFERENCES

1. MILLER JM, HAMBURGER JI, MELLINGER RC: The thyroid scintigram: II The cold nodule. *Radiology* 85: 702-710, 1965
2. MEADOWS PM: Scintillation scanning in the management of the clinically single thyroid nodule. *JAMA* 177: 229-234, 1961
3. KUHL DE: Radioiodine scanning in disease of the thyroid gland. *Radiol Clin North Am* 1: 101-114, 1963
4. DOS REMEDIOS LV, WEBER PM, JASKO IA: Thyroid scintiphotography in 1000 patients: rational use of ^{99m}Tc and I-131 compounds. *J Nucl Med* 12: 673-677, 1971
5. CHARKES ND: Scintigraphic evaluation of nodular goiter. *Semin Nucl Med* 1: 316-330, 1971
6. SILVER S: Scanning in thyroid disease. In *Radioactive Nuclides in Medicine and Biology*, Philadelphia, Lea & Febiger, 1968, pp 97-107
7. MAISEY MN, MOSES DC, HURLEY PJ, et al: Improved methods for thyroid scanning: a correlation with surgical findings. *JAMA* 223: 761-763, 1973
8. MAYNARD CD: The thyroid and parathyroid glands. In *Clinical Nuclear Medicine*, Philadelphia, Lea & Febiger, 1971, p 35
9. BLUM M, GOLDMAN AB, HERSKOVIC A, et al: Clinical applications of thyroid echography. *N Engl J Med* 287: 1164-1169, 1972