

## **CRITICAL EVALUATION OF HEPATIC SCINTIANGIOGRAPHY FOR NEOPLASTIC TUMORS OF THE LIVER**

Robert C. Stadalnik, Sally J. DeNardo, Gerald L. DeNardo, and Antolin Raventos

*Sacramento Medical Center of the University of California School of Medicine, Davis, California*

***Dynamic hepatic scintiangiography increases the specificity of diagnosis of space-occupying lesions of the liver seen on hepatic scintigraphy. The purpose of this study was to evaluate and compare critically this procedure with histologic and radiopaque diagnosis in the evaluation of suspected hepatic neoplasms. Ninety-two patients had hepatic scintiangiography, scintigraphy, and histologic verification. In ten of these patients, the findings of radiopaque arteriography were compared with those of hepatic scintiangiography. In all ten patients with hepatoma, the scintiangiographic and histologic observations correlated; nine of these ten patients had a "tumor stain." Fifty-one of 59 patients with metastases to the liver had scintiangiograms that showed "tumor stain." In 2 of these 59 patients, scintiangiography revealed tumor vascularity whereas the results of scintigraphy were normal. In two of four patients with metastases and two of six patients with hepatomas, scintiangiograms revealed "tumor stain" that was not evident on radiopaque arteriography. Conclusions from this study are: (A) neoplastic arterialization or "tumor stain" is more readily detected by scintiangiography than by radiopaque arteriography; (B) a normal scintigram and a "tumor stain" on the scintiangiogram in a patient with a known primary neoplasm outside the liver is suggestive of hepatic metastases; and (C) a normal scintigram and scintiangiogram make neoplastic involvement of the liver improbable. Dynamic hepatic scintiangiography is a simple, clinically useful method for increasing the specificity of diagnosis of space-occupying lesions of the liver and should be part of the evaluation for possible neoplastic involvement.***

Dynamic hepatic scintiangiography is one method for increasing the specificity of diagnosing space-occupying lesions of the liver seen on hepatic scintigrams (1,2). This method is effective because of the unique dual blood supply to the liver. The normal liver derives approximately 25% of its blood supply from the hepatic artery with the remainder from the portal vein. Most primary and metastatic neoplasms of the liver cause an aberration in the normal pattern such that the blood supply is predominantly or exclusively from the hepatic artery (3-8). Our experience with more than 1,000 hepatic scintiangiograms performed during routine scintigraphy had convinced us of the value of this procedure but a critical evaluation seemed desirable. The purpose of this publication is to compare this procedure, histology, and radiopaque arteriography in the evaluation of hepatic neoplasms.

### **MATERIALS AND METHODS**

Between January 1971 and December 1973, 1,025 patients were referred for hepatic scintigraphy. Hepatic scintiangiography was performed routinely as part of the evaluation of the liver. One-hundred-eighty-nine of these patients were classified by discharge diagnosis as having hepatic metastases or normal livers based on clinical or laboratory data, tissue diagnosis, or hepatic scintigraphy. The ethnic breakdown consisted of 158 whites, 14 blacks, and 17 orientals. In 92 of these 189 patients, histologic examination of the liver was performed within 2 days to 2 months of hepatic scintigraphy and scintiangi-

Received Oct. 4, 1974; revision accepted Jan. 22, 1975.

For reprints contact: Gerald L. DeNardo, Sacramento Medical Center, 2315 Stockton Blvd., Sacramento, Calif. 95817.

**TABLE 1. COMPARISON OF HISTOLOGY WITH SCINTIGRAM AND SCINTIANGIOGRAM**

Histology	Normal	Metastases	Hepatoma
Number of patients	23	59	10
Needle	18	16	4
Operative	0	22	3
Autopsy	5	21	3
Scintigram normal	21	5	0
Scintigram abnormal	2	54	10
Scintiangiogram normal	20	8	1
Scintiangiogram abnormal	3*	51	9

\* One patient had focal arterialization due to renal carcinoma.

ography. The liver tissue specimen was obtained by percutaneous needle biopsy (nonoperative), at operation (operative), and by autopsy (Table 1). Normal histologic findings were observed in 23 patients; in 18, the specimens were obtained by nonoperative biopsy and in five, by autopsy. A histologic diagnosis of hepatoma was obtained in ten patients; four diagnoses were verified by autopsy, one by nonoperative biopsy, two by tissue obtained both nonoperatively and at autopsy, two by tissue obtained by operative means, and one by tissue obtained both operatively and nonoperatively. Histologically, 59 patients were classified as having hepatic metastases; in 21 patients, tissue was obtained at autopsy; in 16, by nonoperative means; in 21, by operative procedures; and 1 patient, by tissue obtained both operatively and at autopsy.

Ten patients underwent radiopaque arteriography, hepatic scintigraphy, and scintiangiography; six of these patients had hepatomas and four had metastases which were histologically verified.

The scintiangiographic studies were performed by the technique described by DeNardo, et al (1). After the intravenous injection of 10 mCi of  $^{99m}\text{Tc}$ -sulfur colloid, scintiphotographs were obtained at 2-sec intervals for 40 sec. At 1 min after administration of the radiopharmaceutical, a "positioning" scintiphotograph was exposed for 500,000 counts. The positioning film was used to determine the area of the hepatic bed for the scintiangiographic interpretation. Routine static hepatic scintiphotographs were obtained 30 min after injection (Fig. 1).

The scintigraphic studies were evaluated in the following manner. The distribution of radioactivity within the liver was categorized as normal, "focal," "multifocal," or "patchy." A focal defect was one that was well-defined and tended to be spherical. Multifocal defects referred to two or more focal defects. A patchy defect was definite but less well defined and in many instances represented a general-

ized irregularity of radioactivity distribution which was difficult to define precisely.

Scintiangiograms were evaluated with reference to aortic filling; the first 8 sec after the initial appearance of the radioactive bolus in the abdominal aorta were classified as the arterial phase. Normally, there was only a small amount of radioactivity in the hepatic bed at this time and this was called "normal arterialization." Abnormally increased radioactivity in the hepatic bed during this phase was classified as patchy, focal, multifocal, or generalized arterialization and was compared with patchy, focal, and multifocal defects seen on the scintigram. "Generalized arterialization" was the term used when the entire hepatic bed showed an increase in radioactivity. Radiopaque arteriography was performed using the percutaneous femoral approach of Seldinger (9).

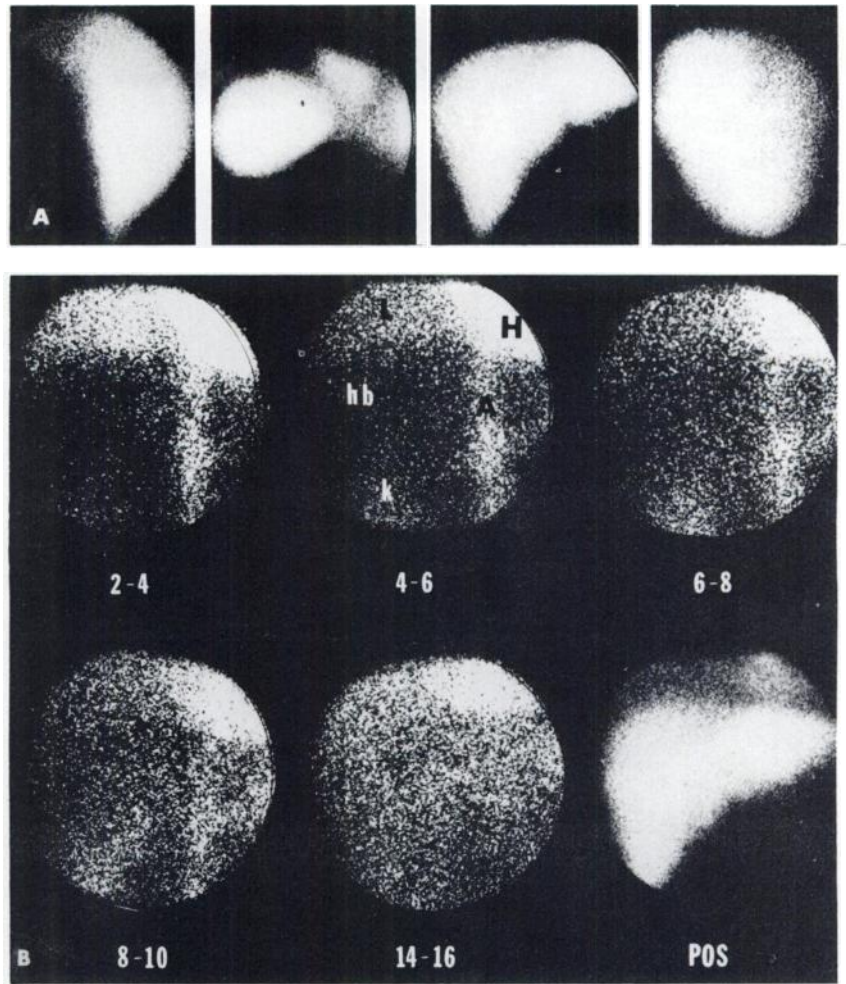
Appropriate sections of the liver were fixed in 10% formalin, stained with hematoxylin-eosin, cut into multiple 5-micron sections, and examined under the microscope.

## RESULTS

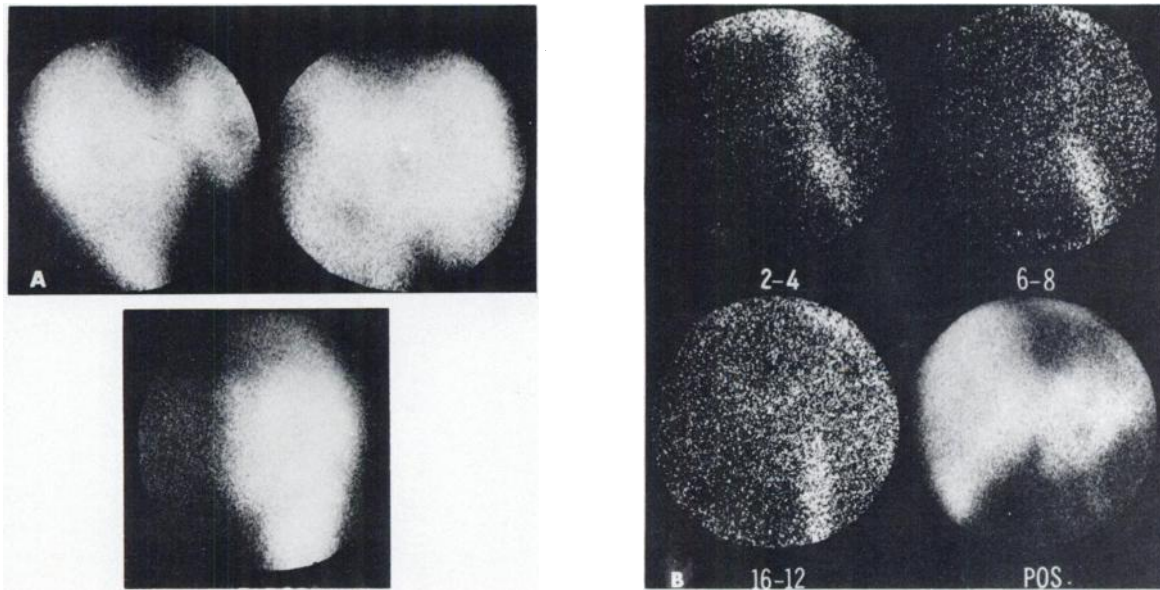
**Patients with normal hepatic tissue** (Table 1). In one of the 23 patients in this classification, the scintigram was normal but the scintiangiogram was abnormal and demonstrated a large arterialized lesion with a necrotic center; this "tumor stain" was judged to be extrahepatic and was correctly interpreted as renal in origin (10). In two patients, both the scintigram and the corresponding scintiangiogram were definitely abnormal (Fig. 2; Table 2). In both of these patients with a known primary malignant lesion elsewhere in the body, the normal histologic specimen was obtained by percutaneous needle biopsy. In 20 patients, both the hepatic scintigram and corresponding scintiangiogram were normal.

**Patients with hepatoma.** There are ten patients with this finding, and in one, multiple focal lesions, as seen on scintigraphy, were avascular throughout all phases of scintiangiography (Table 2). Radiopaque hepatic arteriography also showed the lesions to be avascular (Table 3). Microscopic examination of the tumor tissue showed relative avascularity of the tumor as well as tumor in many of the portal veins. In the other nine patients, hepatic scintiangiography revealed a vascular lesion corresponding to the defect seen on routine scintigraphy (Fig. 3). The vascularity was evident in the early arterial phase, within 4 sec, and persisted into the early venous phase. In one of these nine patients, a portion of the focal lesion was not arterialized due to necrosis of tumor in this area.

**Patients with hepatic metastases.** There were 59 patients with a histologic diagnosis of hepatic metas-



**FIG. 1.** Normal liver. (A) Static hepatic images reveal normal liver as seen on (from left to right) right posterior, left posterior, right anterior, and right lateral views. (B) Hepatic scintiangiogram. During arterial phase (2-4, 4-6, 6-8 sec), radioactivity is visualized in aorta (A) and kidney (k); persistent radioactivity is also seen in heart (H) and right lung (L). Liver (hb), as outlined by positioning film (POS), contains paucity of radioactivity. During venous phase (8-10, 14-16 sec), liver contains increased radioactivity.



**FIG. 2.** Histologically diagnosed normal tissue obtained by closed needle biopsy. (A) Static hepatic images reveal multiple space-occupying lesions throughout liver on right anterior (top left), right lateral (top right), and right posterior (bottom) views. (B) Posi-

tioning film outlines liver with definite space-occupying lesion identified in left lobe of liver. At 2-4 sec after initial appearance of radioactivity in abdominal aorta, patchy arterialization was present within hepatic bed which persisted throughout entire arterial phase.

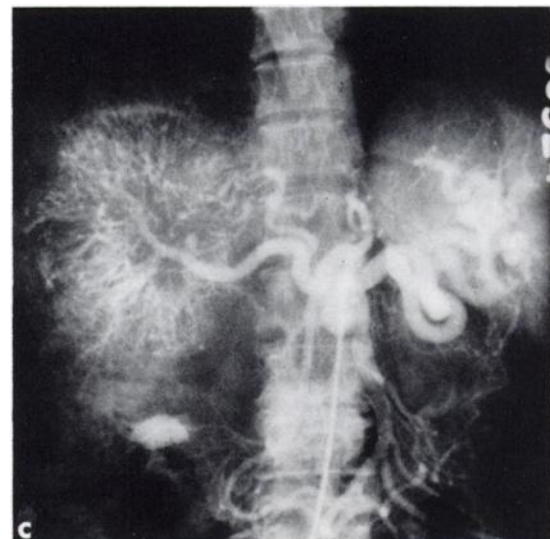
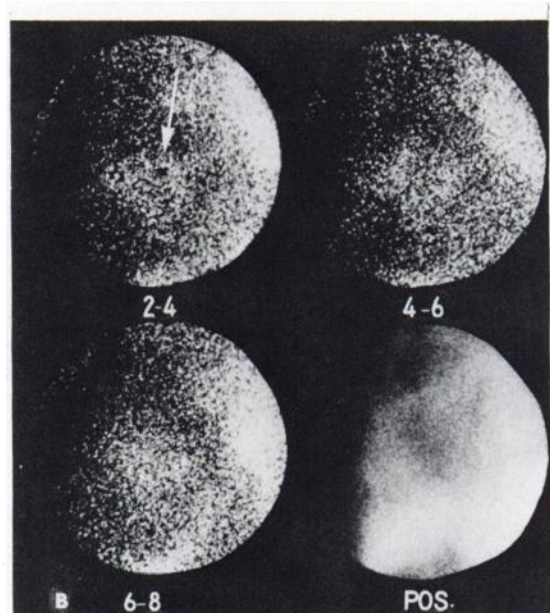
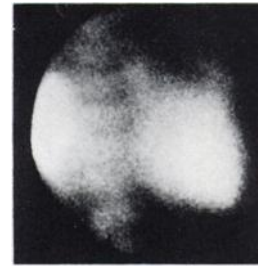
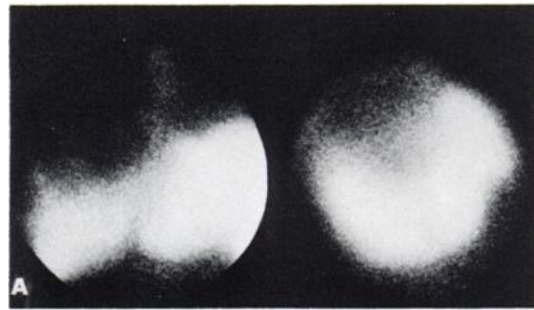
tases; 21 were defined by autopsy material, 21 by operative biopsy, 16 by nonoperative biopsy, and 1 by both operative biopsy and autopsy. The sources of the metastases were: lung, 14; colon, 11; breast, 8; pancreas, 6; stomach, 5; rectum, 4; gallbladder, 2; prostate, 2; and 1 each from kidney, larynx, esophagus, neuroblastoma, ovary, bladder, and sarcoma of the groin. There was no difference in the frequency

**TABLE 2. TWELVE PATIENTS IN WHOM HISTOLOGY DID NOT CONFIRM SCINTIANGIOGRAPHIC DIAGNOSIS**

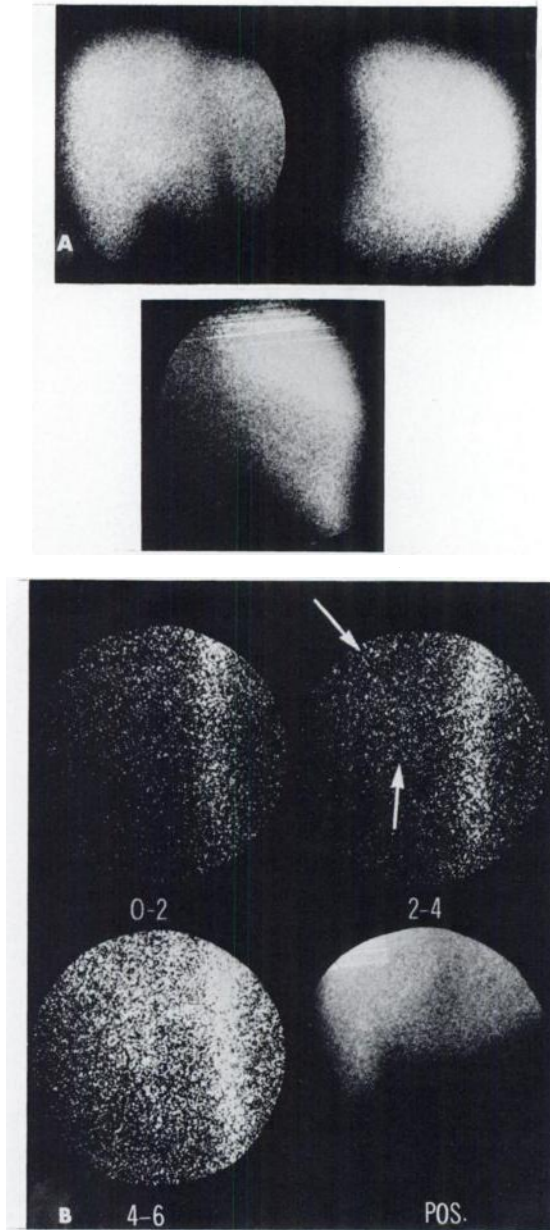
Histology	Scintiangiogram	Scintigram
Normal (3)	Multifocal arterialization (1)	Multifocal (1)
	Generalized arterialization (1)	Multifocal (1)
	Focal arterialization due to renal carcinoma (1)	Normal (1)
Hepatoma (1)	Avascular (1)	Multifocal (1)
Metastases (8)	Normal (8)	Normal (3)
		Patchy (2)
		Multifocal (1)
		Focal (2)

**TABLE 3. COMPARISON OF THE RADIOPAQUE ARTERIOGRAM WITH THE SCINTIANGIOGRAM (TEN PATIENTS)**

Arteriogram	Scintiangiogram	Diagnosis
Scintiangiogram correlated with arteriogram and histologic diagnosis		
Arterialized	Arterialized	Metastases (colon)
Arterialized	Arterialized	Metastases (breast)
Arterialized	Arterialized	Hepatoma
Arterialized	Arterialized	Hepatoma
Arterialized	Arterialized	Hepatoma
Scintiangiogram and arteriogram failed to correlate with histologic diagnosis		
Nonarterialized	Nonarterialized	Hepatoma
Scintiangiogram correlated with histologic diagnosis, but not with arteriogram		
Nonarterialized	Arterialized	Metastases (pancreas)
Nonarterialized	Arterialized	Metastases (prostate)
Nonarterialized	Arterialized	Hepatoma
Nonarterialized	Arterialized	Hepatoma



**FIG. 3.** (opposite) Histologically verified hepatoma. (A) Static hepatic images reveal large, solitary space-occupying lesion in right lobe of liver on right anterior (top left), right lateral (top right), and right posterior (bottom) views. (B) Positioning film defines heart, lower part of right lung, lesion, and liver. At 2-4 sec after initial appearance of radioactivity in abdominal aorta, focal arterialization (arrow) was present and persisted throughout arterial phase (4-6, 6-8 sec); upper part of lesion was not arterialized and was necrotic. (C) Radio-opaque arteriogram demonstrates vascular nature of lesion.



**FIG. 4.** Histologically verified metastases to liver. (A) Static hepatic images reveal normal-appearing liver except for mild enlargement on right anterior (top left), right lateral (top right), and right posterior (bottom) views. (B) Positioning film outlines liver. Diffuse arterialization of hepatic bed is present (upper arrow); it began 0-2 sec after initial appearance of radioactivity in abdominal aorta and persisted throughout arterial phase (2-4, 4-6 sec). Arterialization of liver is similar to arterialization of right kidney (lower arrow).

of occurrence of a "tumor stain" in these various histologic types of metastatic neoplasm.

In three patients, the scintigram and scintiangiogram were normal in the presence of histologic evidence of metastases to the liver; two were found at postmortem examination and one by operative biopsy (Table 2). In one patient, there was a 10-day interval between the study and postmortem examination, and in the second patient, there was a 2-month interval between the study and open biopsy of the

liver. In the third patient, only 1-2-mm subcapsular metastases were seen at postmortem examination performed 2 days after the scintigraphic studies.

In two patients the scintigram was normal, but the scintiangiogram revealed generalized arterialization of the hepatic bed (Fig. 4). Multiple small metastases were seen on microscopic sections obtained at autopsy in one patient and by operative biopsy in the other patient.

In 54 patients, focal, multifocal, or patchy defects were noted on scintigrams. In 34 of these 54 patients there was focal or multifocal arterialization corresponding to focal defects seen on scintigrams. In 15 of these 54 patients there was generalized arterialization of the hepatic bed. Of these 15 patients, 12 had multifocal defects, 1 had a focal defect, and 2 had patchy defects seen on scintigraphy. In 5 of these 54 patients, multifocal or patchy defects on scintigraphy were associated with a normal scintiangiographic pattern (Table 2).

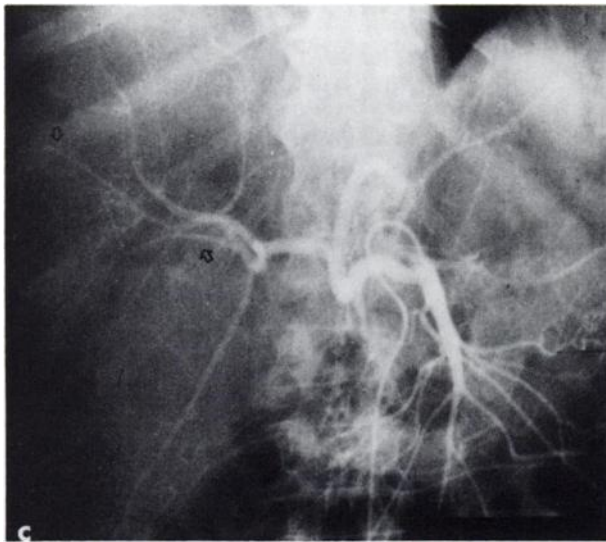
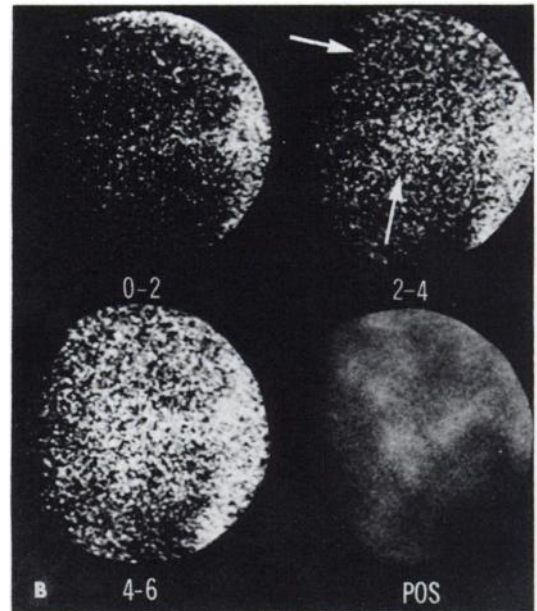
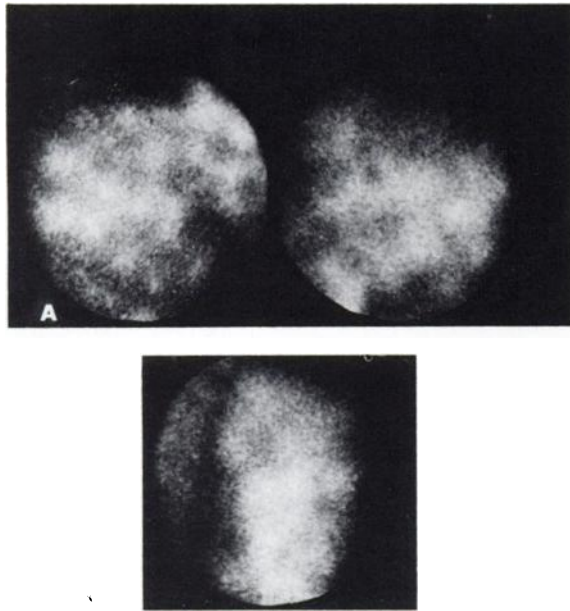
**Correlation of hepatic scintigram, scintiangiogram, and radiopaque arteriogram** *Hepatoma verified histologically.* In four of six patients, the hepatogram phases of the scintiangiogram and radiopaque arteriogram correlated well (Fig. 3, Table 3). In two, they did not correlate and the scintiangiogram correctly defined the vascular nature ("tumor stain") of the lesion and correlated with the histologic findings. The radiopaque arteriogram failed to reveal the tumor stain but did reveal slight irregularity of the vessels in the involved area.

*Metastases verified histologically.* In two of four patients, the radiopaque arteriogram showed avascular space-occupying lesions of the liver whereas in all four patients the scintiangiogram demonstrated vascularity during the arterial phase, representing "tumor stain" (Fig. 5).

#### DISCUSSION

Hepatic scintiangiography is one method for evaluating space-occupying lesions of the liver seen on routine scintigraphy. The attraction of this method has been its ready availability and simplicity.

Percutaneous needle biopsy can miss up to 30% of liver metastases, and selective radiopaque arteriography can miss at least 10% (11). It is well established that a tumor stain is one of the most common and definitive radiopaque arteriographic criterion for the diagnosis of neoplastic diseases of the liver (12,13). Anatomic studies in animals and humans have shown that malignant neoplasms growing in the liver acquire an exclusive blood supply from the hepatic artery (3,6,7). These last two facts are the basis of the role hepatic scintiangiography plays in the detection of neoplasms of the liver. During



**FIG. 5.** Histologically verified metastases to liver. (A) Static hepatic images reveal multiple space-occupying lesions throughout liver on right anterior (top left), right lateral (top right), and right posterior (bottom) views. (B) Positioning film outlines liver. Patchy arterialization of hepatic bed (upper arrow) is present; it began 0-2 sec after initial appearance of radioactivity in abdominal aorta and persisted throughout arterial phase. Arterialization of liver is similar to arterialization of kidney (lower arrow). (C) Radiopaque arteriogram reveals multiple avascular areas stretching and displacing vessels (arrows).

hepatic scintiangiography the "arterialization" of a lesion within the first seconds after the appearance of the radioactive bolus in the abdominal aorta is comparable to the "tumor stain" noted on radiopaque angiography (1).

If the arterialization seen on the scintiangiogram corresponds with a defect seen on the scintigram, neoplastic involvement of the liver is a strong probability. Likewise, if multifocal lesions on scintigraphy are accompanied by generalized arterialization of the hepatic bed, neoplasm is also a high probability. Scintiangiography is, therefore, a method for increasing the specificity of diagnosis. In the presence of lesions smaller than the resolution of present detector systems as well as lesions which are avascular, a "tumor stain" may be absent.

From our series, a normal scintigram and scintiangiogram appear to make neoplastic involvement of the liver improbable. However, scintiangiography by itself is less sensitive than scintigraphy for the detection of space-occupying lesions of the liver (Table 1). There were nine false-negative scintiangiograms in patients with histologic evidence of neoplasm in the liver. In addition, three patients had abnormal scintiangiograms without histologic evidence of neoplasm in the liver. Superficially these would appear to represent false-positive studies but in reality they do not. In two patients, the scintigrams were virtually diagnostic of metastases and the other study revealed an extrahepatic neoplasm (10).

Two other patients with known primary neoplasms outside the liver demonstrated normal scintigrams

with an abnormal scintiangiogram and proved to have hepatic metastases; these represented instances in which scintiangiography was particularly useful. Although this pattern is suggestive of neoplastic involvement of the liver, it may be caused by extrahepatic neoplasms.

In the comparison of hepatic scintiangiography with radiopaque arteriography (Table 3), scintiangiography was found to be a more sensitive method for detecting arterialization or "tumor stain," reflecting increased blood flow through the capillary and sinusoidal vessels more readily. There was no difference by scintiangiography in the frequency of occurrence of a "tumor stain" in the various histologic types of metastatic neoplasms. With radiopaque arteriography, if the primary tumor is vascular such as hypernephroma, carcinoid tumor, or leiomyoma of the gastrointestinal tract, the metastases will be vascular; poorly vascularized primary tumors such as adenocarcinoma of the gastrointestinal tract or pancreas will have avascular metastases by radiopaque arteriography (11-14). The extent and intensity of arterialization appear to correspond to the relative amounts of vascularity and necrosis noted histologically (1).

Since the degree of vascularity of hepatic lesions is well defined by scintiangiography, has good correlation with the histologic findings, and has greater sensitivity than radiopaque angiography, it should be part of the evaluation of the liver for neoplastic involvement.

#### ACKNOWLEDGMENT

This work was presented at the 21st Annual Meeting of the Society of Nuclear Medicine, June 11-14, 1974, San Diego, California. The work was supported in part by grants-in-aid from American Cancer Society DT-45, University of California School of Medicine at Davis Faculty

Research Grant D-912, and the General Research Support Grant of the University of California School of Medicine at Davis.

#### REFERENCES

1. DENARDO GL, STADALNIK RC, DENARDO SJ, et al: Hepatic scintiangiographic patterns. *Radiology* 111: 135-141, 1974
2. WAXMAN AD, APAU R, SIEMSEN JK: Rapid sequential liver imaging. *J Nucl Med* 13: 522-524, 1972
3. ACKERMAN NB, LIEN WM, SILVERMAN NA: The blood supply of experimental liver metastases. III. The effects of acute ligation of the hepatic artery or portal vein. *Surgery* 71: 636-641, 1972
4. BIERMAN HR, BYRON RL, KELLY KH, et al: Studies on the blood supply of tumors in man. III. Vascular patterns of liver by hepatic arteriography in vivo. *J Natl Cancer Inst* 12: 107-131, 1951
5. BREEDIS C, YOUNG G: Blood supply of neoplasms in the liver. *Fed Proc* 8: 351, 1949
6. BREEDIS C, YOUNG G: The blood supply of neoplasms in the liver. *Am J Pathol* 30: 969-985, 1954
7. MANN JD, WAKIM KG, BAGGENSTOSS AH: The vasculature of the human liver: a study by the injection-cast method. *Mayo Clin Proc* 28: 227-232, 1953
8. MCINDOE AH: Vascular lesions of portal cirrhosis. *Arch Pathol* 5: 23-42, 1928
9. SELDINGER SI: Catheter replacement of the needle in the percutaneous arteriography: a new technique. *Acta Radiol [Diagn] (Stockh)* 39: 368-376, 1953
10. COATES G, STADALNIK RC, PALMER JM, et al: Hepatic scintiangiography in malignant parasitic tumors. *J Nucl Med* 15: 137-139, 1974
11. POLLARD JJ, FLEISCHLI DJ, NEBESAR RA: Angiography of hepatic neoplasms. *Radiol Clin North Am* 8: 31-41, 1970
12. NEBESAR RA, POLLARD JS, STONE DL: Angiographic diagnosis of malignant disease of the liver. *Radiology* 86: 284-291, 1966
13. WATSON RC, BALTAHE HA: The angiographic appearance of primary and secondary tumors of the liver. *Radiology* 101: 539-548, 1971
14. ABRAMS HL: *Angiography*. Boston, Little, Brown, 1971, vol 2, pp 983-1001