

SIGNIFICANCE OF ABSENT OR FAINT KIDNEY SIGN ON BONE SCAN

Wilfrido M. Sy, Devayani Patel, and Howard Faunce

*Brooklyn-Cumberland Medical Center
and Downstate Medical Center, State University of New York, Brooklyn, New York*

Seven men, six suffering from widespread bone metastases of prostatic origin and one with urinary bladder carcinoma, demonstrated minimal or no discernible radioactivity in the kidneys and urinary bladder at the time of bone scanning using ^{99m}Tc-stannous polyphosphate. The mechanism behind this scan finding is thought to be rapid and enhanced uptake of the radiopharmaceutical by pathologic bone. The significance of the faint or absent kidney sign in bone scanning, particularly in cases where abnormally homogeneous and symmetric radioactivity exists, is discussed.

The major excretory route of ^{99m}Tc-stannous polyphosphate is the urinary tract, accounting for its intense image on most scans (1). Pathologic conditions of the kidney and bladder are often suspected when defective or asymmetric radioactivity is detected in

these organs during bone scanning (2-4). This communication details our findings in seven patients with extensive bone metastases, who were not in significant renal failure and whose kidneys manifested faint or no radioactivity during bone scanning.

MATERIALS AND METHODS

Six men with extensive bone metastases secondary to prostatic malignancy and one with urinary bladder carcinoma are the subject of this report. Pertinent clinical and laboratory data are summarized in Table 1. Minified 5:1 total-body scans with anterior and posterior projections were performed on all seven patients using the Ohio-Nuclear 84 5-in. dual-headed scanner fitted with 24L low-energy collima-

Received Nov. 12, 1974; revision accepted Jan. 13, 1975.

For reprints contact: Wilfrido M. Sy, Nuclear Medicine Dept., Brooklyn-Cumberland Medical Center, 121 DeKalb Ave., Brooklyn, N.Y. 11201.

TABLE 1. SUMMARY OF PERTINENT PATIENT DATA

Patient (No.)	Age and sex	Clinical data	Diagnosis	BUN (mg%)	Creatinine (mg%)
1	64m	Hematuria and dysuria	Urinary bladder transitional cell carcinoma	29	0.9
2	81m	Hematuria and dysuria; prostatectomy 5 years ago	Undifferentiated carcinoma of prostate	27	2.4
3	50m	Urinary frequency; prostatectomy 3 years ago	Carcinoma of prostate	16	0.9
4	76m	Back pain; prostatectomy 4 years ago	Carcinoma of prostate	18	—
5	71m	Aplastic anemia and fever; prostatectomy 10 years before for benign prostatic hypertrophy	Bone biopsy consistent with prostate adenocarcinoma	18	1.2
6	71m	Nocturia; prostatectomy	Adenocarcinoma of prostate	16	—
7	79m	Generalized weakness; anemia; bone pain; no surgery	Prostate malignancy—based on widespread osteoblastic changes on x-ray, markedly elevated acid phosphatase, and a small hard prostate	22	0.8

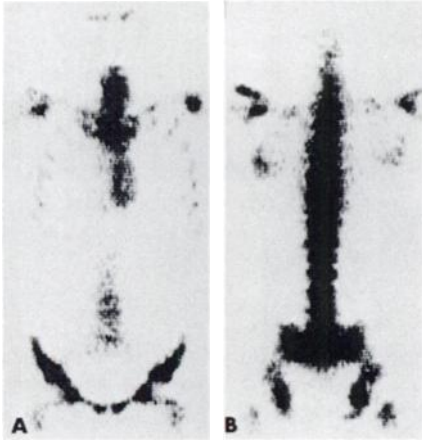


FIG. 1. (A) Anterior and (B) posterior bone scan of Patient No. 5. Note heavy but homogeneous radioactivity in vertebrae, shoulders, and pelvis and absent kidney and bladder radioactivity.

tors about 3 hr after the intravenous administration of 15 mCi of New England Nuclear ^{99m}Tc -stannous polyphosphate. The window was set at 40 keV and a baseline of 120 keV, and data density of about 1,000 counts/cm² with speed of approximately 750 cm/min was used. Patient No. 1 had two separate scans performed 5 months apart. Three-minute preset spot photoscans of desired areas were also performed in each patient using the Dyna-Pic upgraded 2C camera fitted with an ultrafine collimator; 140-keV symmetric peak was used. Patient No. 5 also had a bone marrow scan performed using 2 mCi of ^{111}In -chloride.

SCAN RESULTS

Patient Nos. 3 and 5 showed no radioactivity in the kidneys and bladder. Patient No. 7 had no radioactivity in the kidneys but some radioactivity in the bladder. Barely discernible radioactivity, insufficient to outline the kidneys and bladder, was observed in the other four patients. Patient No. 1 had an initial scan that clearly outlined the left kidney and urinary bladder. Abnormal asymmetric activity was present in the calvarium, vertebrae, shoulders, pelvis, ribs, and sometimes the long bones in all patients except No. 5. The latter showed symmetrically increased radioactivity in the shoulders, ribs, vertebrae, and pelvis (Fig. 1A and B).

DISCUSSION

About 40–50% of the ^{99m}Tc -stannous polyphosphate is eliminated through the urinary tract a few hours after injection, providing sufficient radioactivity to outline kidneys and bladder during bone scanning (1).

The absence or faint delineation of the kidneys and urinary bladder in our patients appears to be the

result of enhanced extraction of the radiopharmaceutical by the bone secondary to the presence of very extensive metastases. In Patient No. 1, for instance, the initial bone scan delineated the left kidney well and the expected radioactivity in the bladder was present at a time when no significant bone involvement was present (Fig. 2). The right kidney was subsequently shown to be small and hydronephrotic on retrograde pyelography. However, a second scan obtained 5 months later when the patient's generalized bone pain had worsened revealed barely discernible radioactivity in the urinary tract; concurrently the radioactivity in bone appears to have been greatly increased (Fig. 3A and B). Avid extraction of ^{99m}Tc -stannous polyphosphate by the skeletal system with failure to outline the kidney and bladder has been described in patients receiving chronic renal dialysis and who manifested the generalized osseous changes of secondary hyperparathyroidism (5). However, none of our patients were in significant

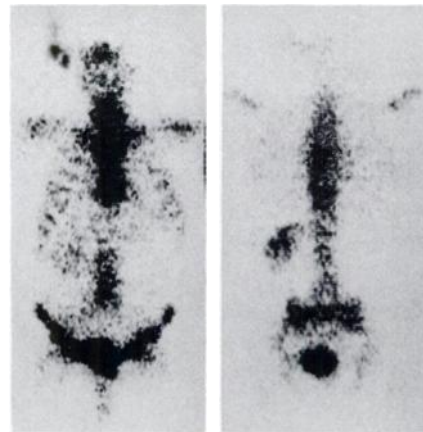


FIG. 2. Left kidney and bladder radioactivity is present in initial bone scan of Patient No. 1. Right kidney is not delineated because of severe hydronephrosis verified on retrograde pyelography.

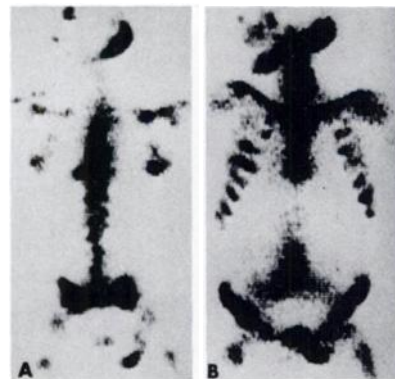


FIG. 3. (A) Left kidney is not delineated and minimal radioactivity is seen in bladder. (B) Concurrently widespread abnormal bone radioactivity is now observed (Patient No. 1).

renal failure or revealed signs of hyperparathyroidism.

Localized or heterogeneous asymmetry of radioactivity on bone scans is reason to suspect or diagnose the presence of osseous metastases. Conversely, symmetric homogeneous radioactivity in corresponding bones of the skeletal system is regarded as normal except in bilateral arthritic processes of major joints where increased symmetric activity may occur. Occasionally cases of disseminated metastatic disease have been reported as normal because of symmetric and uniform uptake in the skeletal system (6-8). Except for Patient No. 5, all of our patients fell within the pattern of intense asymmetric localization of skeletal radioactivity and were associated with extensive bone metastases.

In Patient No. 5, increased skeletal radioactivity in the shoulders, thoracic cage, vertebrae, and pelvis was symmetric and homogeneous in distribution, similar to the scan findings in a case of lymphosarcoma with generalized bone involvement reported by Frankel, et al (6). In their patient, however, the kidneys apparently were outlined. This difference between their patient and ours is not readily accounted for, but could possibly have been due to the more severe bone involvement in our patient as evidenced by a bone marrow packed with malignant cells on bone biopsy and also by the generalized lack of any bone marrow activity on the ^{111}In -chloride scan. The skeletal radiographs of our patient also revealed extensive, diffuse sclerotic changes involving the vertebrae, ribs, shoulders, and pelvis. Thus absent or faint radioactivity in the kidneys on $^{99\text{m}}\text{Tc}$ -stannous polyphosphate scan, especially in cases where the abnormal bone uptake is uniform and symmetric in distribution, may be an important indication of enhanced radiouptake by the bone compartment and hence suggestive of extensive bone abnormality.

The absent or faint kidney sign has also been ob-

served in Paget's disease with very extensive bone involvement (9), and possibly in other clinical conditions that cause abnormal avidity for the radiopharmaceutical by an expanded bone compartment. This abnormal and rapid extraction of the radiopharmaceutical may therefore allow only an insignificant amount of radioactivity to be extracted by the kidneys and visualized at the time of the scan.

ACKNOWLEDGMENT

The authors wish to thank David C. Westring for kindly reviewing the manuscript, Robert Bay for technical assistance, and M. Harris for secretarial help.

REFERENCES

1. SUBRAMANIAN G, MCAFEE JG, BELL EG, et al: Technetium $^{99\text{m}}$ -labeled polyphosphate as a skeletal imaging agent. *Radiology* 102: 701-704, 1972
2. PARK CH, GLASSMAN LM, THOMPSON NL, et al: Reliability of renal imaging obtained incidentally in $^{99\text{m}}\text{Tc}$ -polyphosphate bone scanning. *J Nucl Med* 14: 534-536, 1973
3. JACKMAN SJ, MAKER FT, HATHERY RR: Detection of renal-cell carcinoma with $^{99\text{m}}\text{Tc}$ -polyphosphate imaging of bone. *Mayo Clinic Proc* 49: 297-298, 1974
4. FRANKEL RS, JONES AE, JOHNSON KW, et al: The significance of urinary bladder displacement noted on whole-body ^{18}F bone scintigraphy. *Radiology* 109: 397-399, 1973
5. SY WM, MITTAL AK: Bone scan in anephrics with evidence of secondary hyperparathyroidism. In *Proceedings of First World Congress of Nuclear Medicine*, Tokyo-Kyoto, 1974, pp 981-983
6. FRANKEL RS, JOHNSON KW, MABRY JJ, et al: "Normal" bone radionuclide image with diffuse skeletal lymphoma. *Radiology* 111: 365-366, 1974
7. THRUPKAEW AK, HENKIN RE, QUINN JL III: False negative bone scans in disseminated metastatic disease. *Radiology* 113: 383-386, 1974
8. CHARKES ND, SKLAROFF DM, YOUNG I: A critical analysis of strontium bone scanning for detection of metastatic cancer. *Am J Roentgenol Radium Ther Nucl Med* 96: 647-656, 1966
9. SHIRAZI PH, RYAN WG: Bone scanning in evaluation of Paget's disease. *CRC Crit Rev Clin Radiol Nucl Med* 5: 523-558, 1974