

What Causes Uptake of Technetium-99m Methylene Diphosphonate by Tumors? A Case Where the Tumor Appeared to Secrete a Hypercalcemia-Causing Substance

Charles K. Stone and James C. Sisson

Department of Internal Medicine, Division of Nuclear Medicine, University of Michigan Medical Center, Ann Arbor, Michigan

A patient exhibited an unusual constellation of findings: His extrasosseous lymphoma sequestered [^{99m}Tc]MDP, a bone-seeking agent, while at the same time it appeared to produce a factor that caused hypercalcemia. The dispersed lymphoma cells took up more [^{99m}Tc]MDP in vitro than did cultured lymphoblasts suggesting that the in vivo sequestration may have been, at least in part, an active intracellular process.

J Nucl Med 26:250-253, 1985

Although the technetium-99m- (^{99m}Tc) labeled phosphate compounds have become the standard radiopharmaceuticals for imaging the skeleton, the mechanisms by which these agents bind to bone are not completely understood. Several factors play a role in the sequestration of a diphosphonate by bone—blood flow (1), enzyme activity (especially alkaline phosphatase), and active bone mineralization of hydroxyapatite crystals (2). A radiopharmaceutical such as technetium-99m methylene diphosphonate ([^{99m}Tc]MDP) is concentrated in sites of calcium accretion. In the presence of hypercalcemia, the labeled phosphonates are also sequestered in extrasosseous sites of metastatic calcification such as lung, stomach, and kidney (3). Reports have described labeled-phosphonate binding in a number of extrasosseous neoplasms including lymphoma (4-6), sarcoma (7), and carcinoma (8). Even less is known of the mechanism(s) by which these tumors attract bone-seeking agents than those that enable osseous uptake of the compounds.

We describe a patient who exhibited an unusual constellation of findings. This man had an extrasosseous lymphoma that sequestered [^{99m}Tc]MDP while at the

same time appeared to produce a factor which caused hypercalcemia. An in vitro study showed significantly more uptake of [^{99m}Tc]MDP by the dispersed lymphoma cells from the patient than by cultured lymphoblasts.

CASE REPORT

A 62-yr-old white male presented to our institution in 1983 with complaints of diarrhea, anorexia, fatigue, weight loss, signs of orthostatic hypotension, and hypercalcemia. He had developed chronic renal failure secondary to chronic glomerulonephritis in 1960 and had undergone a cadaveric renal transplant in 1970. Immunosuppressive therapy of azothioprine 150 mg qd and prednisone 10 mg qd were given regularly after the transplantation. He did well until 4 mo prior to admission when he developed his admitting complaints. On admission, systolic blood pressure fell 70 mm of mercury upon standing. His liver was large, firm, and irregular. Laboratory data showed BUN 68 mg/dl, creatinine 7.9 mg/dl, calcium 18.6 mg/dl, phosphate 4.8 mg/dl, lactic acid dehydrogenase 1120 IU/l (normal 60-200), serum glutamic pyruvic transaminase 253 IU/l (2-35), serum glutamic oxalacetic transaminase 221 IU/l (2-35), and bilirubin 1.6 mg/dl. Parathormone directed at the N-terminal was recorded at 18 pg/ml (11-24).

Images of the liver produced by [^{99m}Tc]sulfur colloid portrayed focal defects in the liver and an irregular lower border to the right lobe (Fig. 1). Ultrasound showed hyperechoic areas in the liver. The [^{99m}Tc]MDP images portrayed discrete

Received July 5, 1984; revision accepted Nov. 30, 1984.

For reprints contact: James C. Sisson, MD, Div. of Nucl. Med., University of Michigan Medical Center, 1405 E. Ann St., Box 021, Ann Arbor, MI 48109.

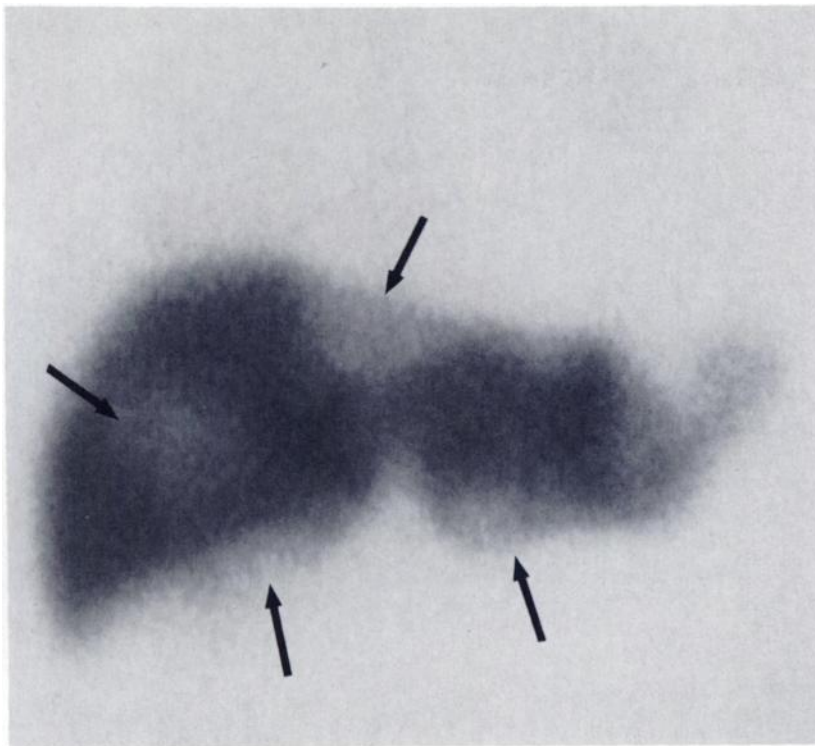


FIGURE 1
 ^{99m}Tc sulfur colloid liver scan. Arrows designate focal areas of decreased uptake of ^{99m}Tc sulfur colloid by large cell lymphoma involving liver

concentrations of radioactivity in the liver corresponding to the abnormalities seen on the ^{99m}Tc sulfur colloid scan (Fig. 2). Only one bone abnormality was seen, a small focal defect in a posterior rib.

At laparotomy, a large tumor was found replacing part of the lower right lobe of the liver and appearing as separate deposits in a pattern corresponding to the abnormalities seen on the ^{99m}Tc MDP study. The biopsy was described on gross examination as tan homogeneous tissue, but, microscopically as much as half of the specimen was necrotic. Large, poorly cohesive cells with vesicular nuclei were seen and three foci of calcification were seen ranging from 1×0.5 to 2×0.5 mm. The pathological diagnosis was poorly differentiated large cell lymphoma.

Immunohistochemical staining of the tumor detected light chains but no B-1, kappa, or lambda chains. Alpha-1-chymotrypsin and muramidase were also absent. T-cell markers T_4 , T_8 , T_{11} were not found.

The patient's hypercalcemia was refractory to saline hydration and furosemide diuresis but lessened following intermittent boluses of mithramycin. However, the hypercalcemia resolved after chemotherapy (cyclophosphamide, doxorubicin hydrochloride, prednisone, and vincristine) was given for the lymphoma. Unfortunately, repeat images with ^{99m}Tc MDP were not made when he exhibited normocalcemia.

In Vitro Assay of ^{99m}Tc MDP Uptake

The large cell lymphoma tissue obtained by liver biopsy and cultured lymphoblasts were handled in the same manner. Each type of cell was placed in a solution of 80% RPMI media and 20% fetal calf serum, then digested in collagenase 3000 U in 30 ml of physiologic buffered saline for 2 hr. Solutions were filtered through wire mesh screen, centrifuged, and resus-

pended in minimal essential media (MEM-1). The cells were passed through 27- μ nylon filter and finally diluted to 1.5 million cells/cc in 4-1 ml aliquots. Trypan blue dye exclusion showed cellular viability of more than 90%.

Technetium-99m MDP was diluted in (MEM-1) to a final concentration of 4 $\mu\text{Ci/ml}$. The aliquots were incubated at 37°C for 15 min after the addition of 0.1 ml of ^{99m}Tc MDP solution to each aliquot. The aliquots were immediately iced after incubation and centrifuged at 800 rpm at 4°C for 5 min. They were washed twice with iced 1.0 ml of phosphate buffered glucose solution at pH 7.3. Pellets of the cells were resuspended in 1.0 ml of physiologic buffered saline and counted in an automated gamma counter. Counts of two vials with 0.1 ml ^{99m}Tc MDP were used as standards and tubes without cells served as background activity.

Mean counts of ^{99m}Tc MDP in the two types of cells were expressed as percentage of the total count and compared by t-test.

RESULTS

Table 1 gives results of uptake of ^{99m}Tc MDP by the cells. The large cell lymphoma tissue sequestered 1.7 times more ^{99m}Tc MDP per million cells ($p < 0.01$).

DISCUSSION

The unusual aspect of this case was the combination of two factors: concentration of ^{99m}Tc MDP by the lymphoma and hypercalcemia related to the presence of the lymphoma. Thus, ^{99m}Tc MDP, an agent that usually accrues in sites of calcification, localized in a tumor