

PSEUDOTUMORS IN ACUTE HEPATITIS

The November issue of the *Journal* contains a case report in which the authors note that their case is only the second one reporting discrete nonfunctional pseudotumorous regions in this disease (1). It seems relevant to mention a patient we had in 1972.

An afebrile 34-year-old man presented after 1 month of weakness and loss of appetite. He had scleral icterus but no other pertinent physical findings. Laboratory data included an alkaline phosphatase, 37 U (normal less than 25 U) SGOT, 378; SGPT, 93; total bilirubin, 1.8 with a direct of 0.9. The Australian antigen was negative. A barium meal was normal, but the gallbladder was not visualized.

The clinical impression was viral hepatitis, but doubt was raised when we noted a large filling defect in the liver about the portal region in a scan using ^{99m}Tc -sulfur colloid (Fig. 1). The spleen was normal size. Biopsy was performed 4 days later in the region of the filling defect. The specimen (Fig. 2) yielded a basically preserved liver architecture with multiple clusters of necrotic and degenerating cells. No evidence of cholangitis or malignancy was noted and the diagnosis was subacute hepatitis with a random pattern suggesting viral etiology. The patient recovered quickly with all symptoms, physical findings, and laboratory results returning to normal.

We had done very few scans on patients with acute hepatitis but apparently such scans as ours and that done by Winston, et al and Shapiro are occasionally seen at large medical centers but seldom reported (2). The distinct filling defects in acute hepatitis should be accepted as part of the expected findings on nuclear imaging although this was not apparent in earlier reviews. Realization of this can prevent grasping for another diagnosis in a patient with a filling defect on scan, and who, by all other evidence, appears to have acute hepatitis. This phenomenon should not be surprising considering the pathologic

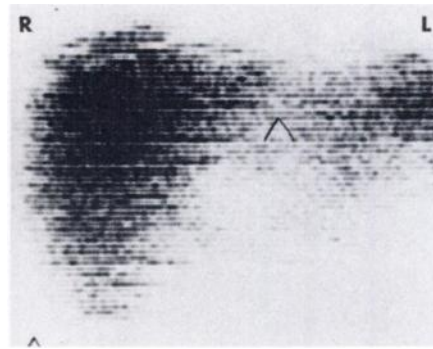


FIG. 1. Anteroposterior liver scan.

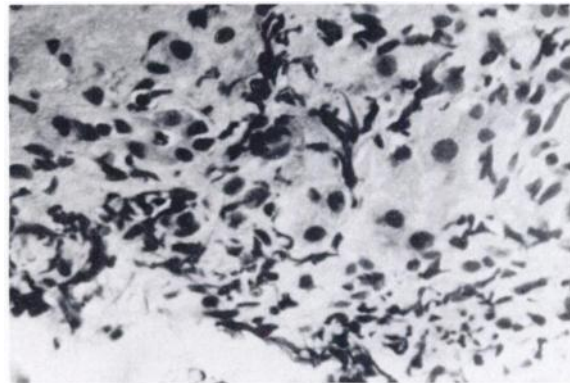


FIG. 2. Liver biopsy.

evidence. Regions of severe involvement have been seen in livers that otherwise have spotty involvement (3). The lack of phagocytic function is not only probably due to actual reticuloendothelial cellular damage which does occur in hepatitis but also may be due to geometric factors as pointed out by Koenigsberg, et al (4). They noted that hepatocyte swelling would greatly diminish the number of reticuloendothelial cells per unit area.

PAUL J. MYERSON
The Griffin Hospital
Derby, Connecticut

THE AUTHOR'S REPLY

We thank Dr. Myerson for his additional case report. Interpreting abnormalities in tracer accumulation at the porta hepatis region is always difficult but this could certainly be considered a pseudotumor. A followup study would have been of great interest.

We could not, however, concur that such focal defects "should be accepted as part of the expected findings on nuclear imaging" in acute hepatitis without some qualification. It is still, in our experience,

sufficiently unusual that some sort of verification that one is dealing with only acute hepatitis is warranted. Although one might wish to defer a biopsy, at least a followup scan should be planned.

M. A. WINSTON
Veterans Administration
Wadsworth Hospital Center
Los Angeles, California

REFERENCES

1. WINSTON MA, SHAPIRO M: Pseudotumors in acute hepatitis. *J Nucl Med* 15: 1039-1040, 1974
2. FREEDMAN G, GOTTSCHALK A: Personal communication, 1974
3. POPPER H, SCHAFFER G: *Liver: Structure and Function*. New York, McGraw-Hill, 1957, pp 428-438
4. KOENIGSBERG M, FREEMAN LM: Intrahepatic focal lesions in acute viral hepatitis. *J Nucl Med* 14: 612-614, 1973

The Paul C. Aebersold Award for Outstanding Achievement in Basic Science Applied to Nuclear Medicine

Nominations are invited for this award, which commemorates the contributions of Dr. Paul Clarence Aebersold to the applications of nuclear physics to nuclear medicine and radiation biology, and his contributions to the Society of Nuclear Medicine.

Dr. Aebersold contributed greatly to the emergence of nuclear medicine as a discipline by his energetic leadership in the provision of cyclotron-generated and reactor-produced radionuclides, and by his numerous publications and lectures.

Above all, the Society thus signifies symbolically its appreciation of the warm and vital person who became its first Honorary Member and whose enthusiastic encouragement and support contributed importantly to the formation and success of the Society of Nuclear Medicine.

Nominations should be supported by the curriculum vitae of the nominee and at least two letters supporting the nomination. These letters should describe briefly the contributions in basic science for which the nominee is proposed. The nominee need not be a member of the Society of Nuclear Medicine.

Please submit nominations and supporting documents to:

BRYAN R. WESTERMAN, Ph.D.
Committee on Awards
Northwestern Memorial Hospital
Department of Nuclear Medicine
Superior St. and Fairbanks Ct.
Chicago, Ill. 60611

**Deadline for 1976 nominations:
November 1, 1975**