

# TECHNETIUM-99m-PYRIDOXYLIDENEGLUTAMATE: A NEW HEPATOBILIARY RADIOPHARMACEUTICAL. II. CLINICAL ASPECTS

P. M. Ronai\*, R. J. Baker, J. C. Bellen, P. J. Collins, P. J. Anderson, and H. Lander

*Institute of Medical and Veterinary Science, Royal Adelaide Hospital  
and University of Adelaide, Adelaide, South Australia*

*Technetium - 99m - pyridoxylidene-glutamate (<sup>99m</sup>Tc-PG) is a nontoxic radiopharmaceutical that was found to undergo rapid biliary excretion in normal humans. The biliary tree and gallbladder were seen within 10-15 min of injection and by 20 min marked accumulation of radioactivity was noted in the gallbladder and gastrointestinal tract. Of ten "control" volunteers, seven had normal <sup>99m</sup>Tc-PG-cholescintigrams. In the remaining three, the gallbladder was not visualized. Gallbladder disease was not excluded in these three subjects.*

*Of 24 patients referred for investigation of right upper quadrant abdominal pain, 13 proved to have gallbladder disease. All seven patients with acute cholecystitis and one of four patients with chronic cholecystitis had nonvisualization of the gallbladder on the cholescintigram whereas five patients with chronic cholecystitis or cholesterolosis had normal cholescintigrams. Six of the eight patients with nonvisualization of the gallbladder on cholescintigram had contrast radiologic studies (oral cholecystogram or intravenous cholangiogram or both), and in all six, nonvisualization of the gallbladder was also reported on the contrast study. Cholescintigraphy was found to be greatly inferior to contrast radiologic studies in the detection of gallbladder stones.*

*Eleven patients had complete extrahepatic biliary obstruction and this diagnosis was correctly made in all 11 by the cholescintigram. Fourteen patients had incomplete extrahepatic biliary obstruction. The correct diagnosis was made on the cholescintigram in seven but in the remaining seven it was not possible to distinguish between incomplete extrahepatic biliary obstruction and hepatocellular disease. Malignant lesions (carcinomas of head of pancreas, gallbladder, common bile duct or ampulla of Vater) were the cause of obstruction in 10 of*

*the 25 patients with complete or incomplete obstruction and the diagnosis of obstruction due to malignancy was correctly made in 8 of these 10 by means of a scintigraphic equivalent to Courvoisier's sign. Finally, 11 patients had hepatocellular disease and a nonspecific pattern consistent with either incomplete biliary obstruction or hepatocellular disease was observed on the cholescintigram in all 11.*

*The <sup>99m</sup>Tc-PG cholescintigram is suggested for a role complementary to that of contrast radiologic studies in the preoperative investigation of patients with possible surgical disease of the biliary tract. Contrast radiologic techniques are advocated as being more appropriate in the nonjaundiced patient with suspected gallbladder disease whereas the <sup>99m</sup>Tc-PG cholescintigram is advocated as being more appropriate in the patient with jaundice. The value of the <sup>99m</sup>Tc-PG cholescintigram lies in the confidence with which complete extrahepatic biliary obstruction can be diagnosed. The "scintigraphic Courvoisier's sign" seems a useful indicator of malignant obstruction.*

Iodine-131-rose bengal has been used for many years for imaging and functional assessment of the hepatobiliary system. The availability of <sup>99m</sup>Tc and more recently of <sup>123</sup>I has stimulated a search for alternatives to <sup>131</sup>I-rose bengal in an effort to obtain higher quality images of the biliary tree. These have included <sup>99m</sup>Tc-penicillamine (1,2), <sup>99m</sup>Tc-dihydrothioctic acid (3-5), <sup>99m</sup>Tc-tetracycline (6), <sup>99m</sup>Tc-

Received Dec. 30, 1974; revision received March 21, 1975.

For reprints contact: P. M. Ronai, Box A034, University of Colorado Medical Center, 4200 E. 9th Ave., Denver, Colo. 80220.

\* Present address: Div. of Nuclear Medicine, Dept. of Radiology, University of Colorado Medical Center, Denver, Colo. 80220.

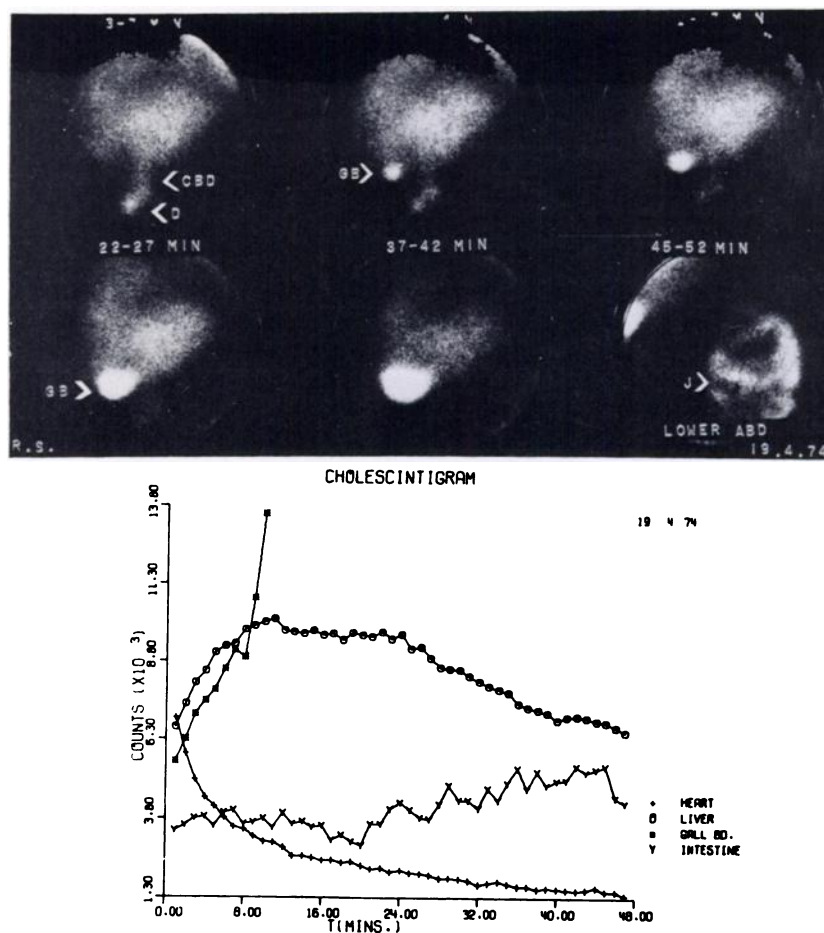
mercaptoisobutyric acid (7),  $^{123}\text{I}$ -iodobromsulphalein (8),  $^{123}\text{I}$ -indocyanin green (9), and  $^{123}\text{I}$ -asialo- $\alpha_1$ -acid glycoprotein (10). Many of these agents have been tried only in experimental animals. Where early human trials have been reported, one or more of the following problems have been encountered: (A) slow biliary excretion of the radiopharmaceutical requiring 90–180 min before adequate gallbladder images can be obtained; (B) insufficient biliary concentration of radioactivity to allow imaging of the bile ducts; (C) frequent failure of entry of the radiopharmaceutical into the normal gallbladder, requiring the use of cholecystokinin to empty the gallbladder before administration of the radiopharmaceutical. Finally, none of the published material on the radiopharmaceuticals previously described demonstrates the clinical value of the particular agent in the investigation of the jaundiced patient.

Technetium-99m-pyridoxylidene-glutamate ( $^{99\text{m}}\text{Tc}$ -PG) is a new radiopharmaceutical that we have found to be rapidly excreted in the bile of experimental animals and humans. The method of preparation, quality control, and animal studies are described elsewhere (11). In this paper we report our clinical experience with  $^{99\text{m}}\text{Tc}$ -PG in control subjects and

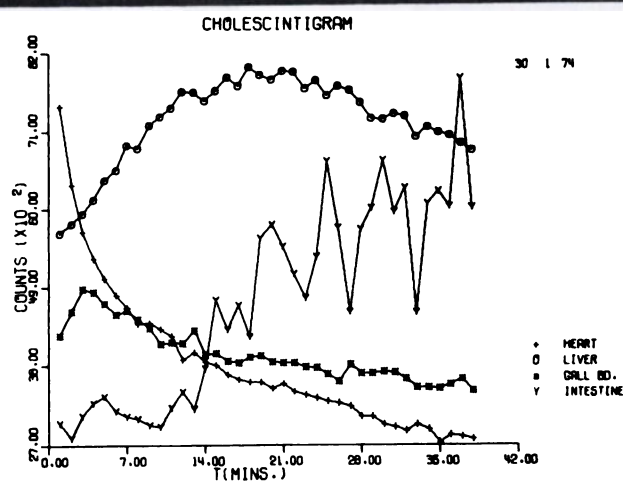
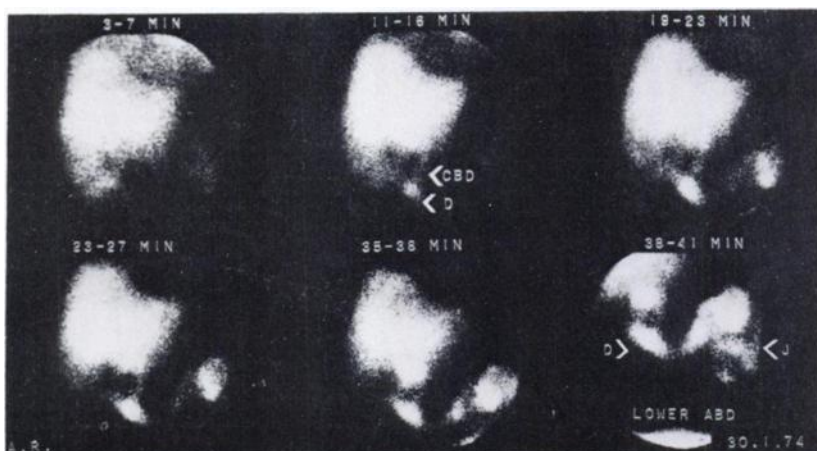
patients referred for the investigation of right upper quadrant abdominal pain or jaundice. Our early findings with this radiopharmaceutical have been previously reported (12).

#### MATERIALS AND METHODS

Technetium-99m-PG was prepared in either ready-to-use form (11) or in "kit" form (to be described in a later communication). All patients investigated were adults and were given a standard dose of 5–6 mCi intravenously. No patient preparation or premedication was used. In the first minute after injection, the blood pool image of the liver, as seen on the persistence oscilloscope of the scintillation camera (Searle Radiographics Inc., Pho/Gamma HP with 4,000-hole collimator), was used to position the liver in the field of view of the camera detector. Sequential 3–5-min scintigrams were then recorded on 35-mm and Polaroid film for 45–60 min after injection. Data were concurrently recorded on digital magnetic tape through a 1,600-word memory (RIDL Model 24-3) after interim storage in  $40 \times 40$  format. Four regions of interest of equal area were selected over heart, liver, gallbladder, and duodenum on tape playback and the data were subsequently analyzed off-



**FIG. 1.** Normal  $^{99\text{m}}\text{Tc}$ -PG cholescintigram. Selected frames from sequential study showing common bile duct (CBD) and duodenum (D) at 3–7 min, gallbladder (GB) at 7–12 min, and jejunum (J) at 45–52 min. Time-activity curves (below) show data for regions of interest positioned over cardiac blood pool, liver, gallbladder, and duodenum. Gallbladder curve has gone off scale by 10 min. Saw-tooth pattern of duodenal curve represents peristaltic activity (seen better in Fig. 2).



**FIG. 2.** Technetium-99m-PG cholecintigram in patient with acute cholecystitis. Gallbladder not visualized at any stage of study. Common bile duct well seen and free passage of tracer into duodenum noted. At operation, tense, acutely inflamed gallbladder found (histologic examination revealed acute or chronic cholecystitis) and common bile duct noted to be only 4 mm in diameter. Time-activity curves show small early peak in gallbladder region due to "shine-through" of renal activity but this has disappeared by 10 min. Duodenal peristaltic activity is striking.

line using a CDC 6400 computer. Time-activity curves were automatically generated for each region of interest at the end of the analysis using an incremental plotter. Additional scintigrams were recorded at 18 hr after injection in those patients in whom satisfactory images of the biliary tree were not obtained within the first hour after injection.

Contrast radiologic studies of the biliary tree comprising oral cholecystogram, intravenous cholangiogram, percutaneous cholangiogram, and operative cholangiogram were performed at the discretion of the patient's attending physician or surgeon. Radiologic studies were reviewed independently of the cholecintigrams by one of the authors (PJA).

Case records of all patients were followed up a minimum of 1 month and a maximum of 12 months after the cholecintigram to obtain the results of surgical procedures and to reach a definitive final diagnosis in each case. A total of 80 consecutive cholecintigrams were reviewed, representing 80 patients. Ten patients were excluded because of incomplete followup data, leaving 70 patients to be included in the study. These were divided into three groups: (A) ten control subjects comprising patients with disorders judged not to involve the hepato-

tobiliary system—all of these patients gave informed consent, (B) twenty-four patients referred for the investigation of right upper quadrant abdominal pain, and (C) thirty-six patients referred for investigation of jaundice.

#### RESULTS

No patient studied with  $^{99m}\text{Tc}$ -PG complained (either spontaneously or on direct questioning) of any symptoms which could in any way be related to the administration of the radiopharmaceutical. Nor did scrutiny of biochemical profiles reveal any alteration in liver enzymes or other biochemical parameters which were not consistent with the natural history of the disease process being investigated.

**Control subjects.** The most striking feature of the normal  $^{99m}\text{Tc}$ -PG cholecintigram was the rapid appearance of the radiopharmaceutical in the biliary tree. The gallbladder and common bile duct were normally seen within the first 10–15 min after injection (Fig. 1). Duodenal peristalsis (seen as a sawtooth pattern in the duodenal time-activity curve) usually prevented accumulation of radioactivity in the duodenum. However, marked accumulation of excreted tracer was seen in the jejunum where it

**TABLE 1. RESULTS OF CHOLESCINTIGRAMS IN PATIENTS WITH "ABDOMINAL PAIN FOR INVESTIGATION"**

Cholescintigram findings	Diagnosis	Patients (No.)
Normal cholescintigram	Chronic cholecystitis, cholelithiasis*	3
	Chronic cholecystitis†	1
	Cholesterolosis, cholelithiasis*	1
	Pancreatitis‡	1
	Myocardial infarct†	1
	Urinary tract infection†	1
	Gastritis‡	1
Normal post-cholecystectomy study	Pancreatitis†	1
	Cholangitis†	1
	Intermittent obstruction (stone)*	1
	"Psychogenic" pain†	1
	Urinary tract infection†	1
Nonvisualization of gallbladder	Cause of pain uncertain	2
	Acute on chronic cholecystitis*	7
	Chronic cholecystitis*	1
	Total	24

\* Confirmed by operation.  
† Clinical/laboratory diagnosis.  
‡ Confirmed by endoscopy.  
No patients in this group had a negative gallbladder shadow on cholescintigram.

often vividly outlined the convoluted course of this portion of the small intestine (see final frame in Fig. 1).

Seven of the ten control subjects had normal cholescintigrams. In the remaining three, the gallbladder did not concentrate radioactivity up to 18 hr after injection. Two of these three had a history suggestive of chronic gallbladder disease on subsequent questioning. Unfortunately, no followup investigations relevant to the biliary tree were performed and the cause of the abnormal cholescintigram in these three subjects must remain uncertain at this time.

**Patients with "abdominal pain for investigation."**

Of 24 patients referred for the investigation of right upper quadrant abdominal pain, 13 proved to have gallbladder disease. All seven patients with histologically proven acute cholecystitis had nonvisualization of the gallbladder on cholescintigraphy (Fig. 2, Table 1). Cholescintigram results in patients with chronic cholecystitis, cholesterolosis of the gallbladder, and a variety of abdominal syndromes not involving the gallbladder are listed in Table 1.

Of the 24 patients in the "abdominal pain for investigation" group, 15 had contrast radiologic studies in addition to the cholescintigram. Results of contrast studies are given in Table 2. There was excellent correlation between contrast studies and the cholescintigram.

**Patients with "jaundice for investigation."** The cholescintigram in the jaundiced patient took one of three forms:

1. *Characteristic of complete extrahepatic biliary obstruction:* no concentration of radiopharmaceutical in the biliary tree or gastrointestinal tract up to 18 hr after injection with or without a negative gallbladder image (i.e., a defect in the liver or background activity in the region of the gallbladder).
2. *Characteristic of incomplete extrahepatic biliary obstruction:* delayed secretion of radiopharmaceutical into the gastrointestinal tract associated with either a positive image of a distended common bile duct or a negative image of the gallbladder.
3. *Consistent with either incomplete extrahepatic biliary obstruction or hepatocellular disease:* delayed secretion of radiopharmaceutical into the gastrointestinal tract without a positive image of a distended common bile duct or negative image of the gallbladder.

Cholescintigrams of a patient with complete extrahepatic biliary obstruction due to a postoperative stricture of the common bile duct and a patient with complete obstruction due to carcinoma of the head of the pancreas are shown in Figs. 3 and 4, respectively (see legends of Figs. 3 and 4 for important features).

The presence of a defect in the region of the gallbladder (as distinct from a nonvisualized gallbladder) in the scintigram of the jaundiced patient was seen in eight out of ten patients with biliary obstruction due to a malignant lesion, comprising four out of six patients with carcinoma of the head of the pancreas, two out of two patients with carcinoma of the gallbladder, one patient with carcinoma of the common bile duct, and one patient with carcinoma of the ampulla (Table 3). In the two patients with carcinoma of the head of the pancreas where a negative gallbladder image was not seen, the scintigrams were of poor technical quality. A negative gallbladder image was not seen in any of 15 patients with complete or incomplete biliary obstruction due to stone or stricture.

The cholescintigram of a patient with incomplete extrahepatic biliary obstruction is shown in Fig. 5.

A distended common bile duct, as exemplified in Fig. 5, was observed in five patients with incomplete biliary obstruction due to stone or stricture. A further six patients with incomplete obstruction due to stone or stricture (presumably of more severe degree) had cholescintigraphic findings similar to those of complete obstruction except for the appearance

**TABLE 2. COMPARISON OF CHOLESCINTIGRAM AND CONTRAST RADIOLOGIC PROCEDURES IN PATIENTS WITH "ABDOMINAL PAIN FOR INVESTIGATION"**

Patient No.	Cholescintigram	Oral cholecystogram	Intravenous cholangiogram	Operative cholangiogram	Final diagnosis
7	Normal	Multiple radiolucent stones			Chronic cholecystitis; cholelithiasis*
8	Nonvisualization of gallbladder	Nonvisualization of gallbladder			Acute on chronic cholecystitis; cholelithiasis*
9	Normal postcholecystectomy study		Minimally dilated common bile duct; normal postcholecystectomy study		Cause of pain uncertain
11	Nonvisualization of gallbladder		4-mm diam common bile duct; nonvisualization of gallbladder	Small diameter common bile duct again noted	Acute on chronic cholecystitis; cholelithiasis*
14	Nonvisualization of gallbladder		Normal common bile duct; nonvisualization of gallbladder	Technically unsuccessful	Acute on chronic cholecystitis; cholelithiasis*
16	Normal		Normal		Pancreatitis†
17	Normal	3 radiolucent stones; poor gallbladder contraction			Cholesterosis; cholelithiasis*
20	Normal postcholecystectomy study		Poor dye concentration but otherwise normal		Urinary tract infection†
21	Normal			Common bile duct normal	Chronic cholecystitis cholelithiasis*
22	Normal	Unsuccessful			Myocardial infarct†
23	Normal postcholecystectomy study		Normal common bile duct; normal postcholecystectomy study		Cause of pain uncertain
26	Nonvisualization of gallbladder	Nonvisualization of gallbladder			Chronic cholecystitis*
35	Normal postcholecystectomy study		Unsuccessful	Small stone in lower end of common bile duct	Choledocholithiasis intermittent obstruction*
38	Nonvisualization of gallbladder	Nonvisualization of gallbladder	Normal common bile duct; nonvisualization of gallbladder		Acute on chronic cholecystitis*
45	Nonvisualization of gallbladder	Nonvisualization of gallbladder			Acute on chronic cholecystitis*

\* Confirmed by operation.  
† Clinical/laboratory diagnosis.

of gastrointestinal radioactivity (usually in the colon) in the 18-hr scintigrams.

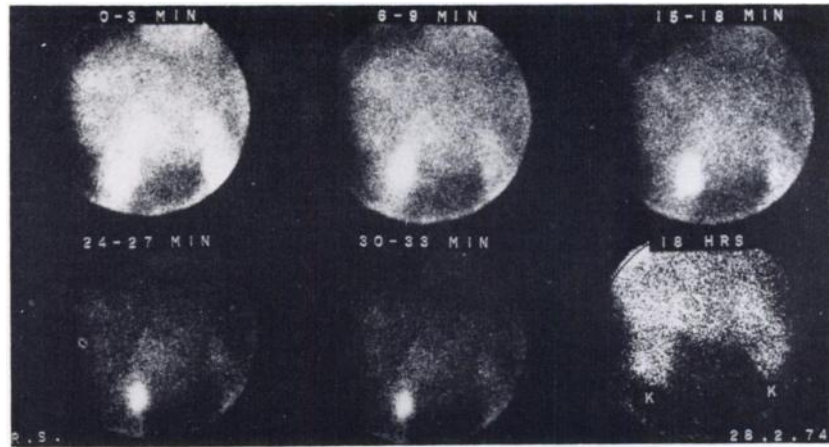
The latter pattern was also observed in all ten patients with hepatocellular disease (Fig. 6). Accordingly, if this latter pattern was seen, it was not possible to differentiate between incomplete obstruction and hepatocellular disease on the basis of the cholescintigram alone.

Preoperative contrast radiologic techniques were found to be of less value in the jaundiced group than in the group with abdominal pain. This is a well-recognized deficiency of contrast radiologic tech-

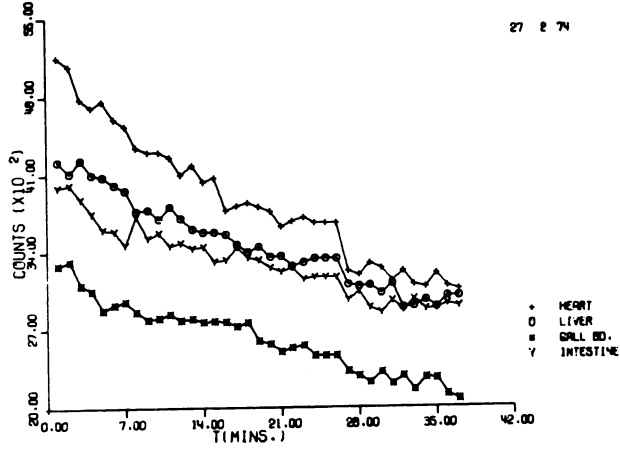
niques and in fact only 7 of 36 patients in the jaundiced group had an oral cholecystogram or intravenous cholangiogram. Results are given in Table 4. In only three cases was the contrast study successful and in all three the jaundice was intermittent and the contrast study was performed between episodes of jaundice.

#### DISCUSSION

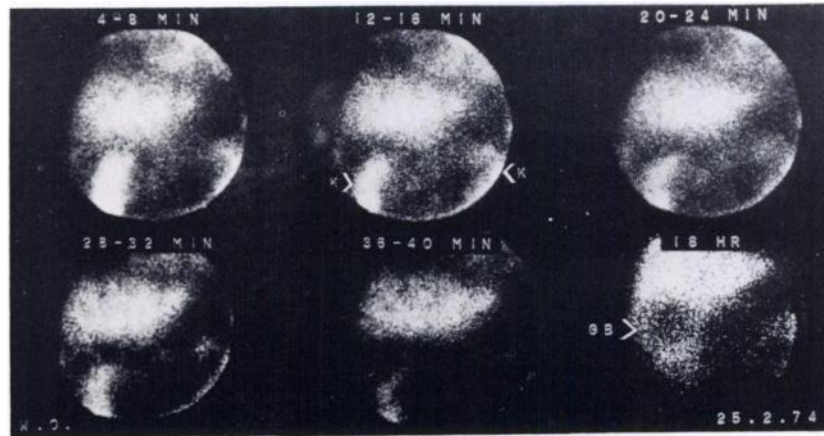
Technetium-99m-PG is a nontoxic radiopharmaceutical that was found to be free from clinical or biochemical sequelae in the doses used. It undergoes



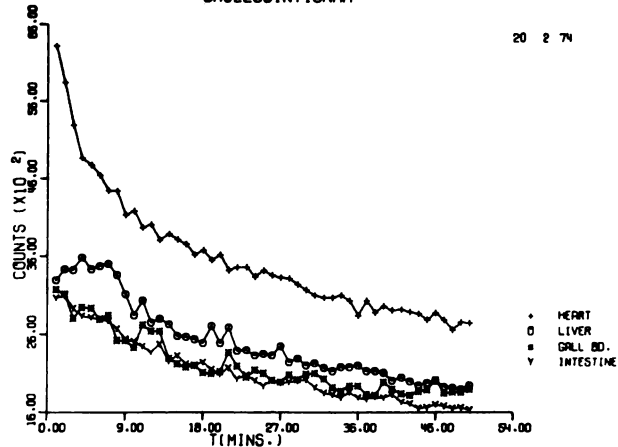
CHOLESCINTIGRAM



**FIG. 3.** Technetium-99m-PG cholescintigram in patient with complete extrahepatic biliary obstruction due to postoperative stricture of bile duct. Scintigrams show blood pool images of heart and liver and excretion of tracer by kidneys. (Tracer does not localize in the biliary tree in complete biliary obstruction). "Hot spot" below liver represents delayed excretion by right kidney. Scintigram at 18 hr (last frame) shows radioactivity in liver and kidneys but not in gastrointestinal tract. Time-activity curves show lack of active accumulation of tracer in liver, gallbladder, or duodenum, all curves being roughly parallel to cardiac blood pool curve. (Positioning of regions of interest for gallbladder and duodenum approximate only.)



CHOLESCINTIGRAM



**FIG. 4.** Technetium-99m-PG cholescintigram in patient with complete biliary obstruction due to carcinoma of head of pancreas. Appearances are similar to those in Fig. 3 except for defect in lower part of right lobe of liver due to grossly distended gallbladder ("scintigraphic Courvoisier's sign").

TABLE 3. RESULTS OF CHOLESCINTIGRAMS IN PATIENTS WITH "JAUNDICE FOR INVESTIGATION"

Cholescintigram findings	Diagnosis	Patients (No.)	Bilirubin (mg/100 ml)	Negative gall-bladder image
Cholescintigram characteristic of complete extrahepatic obstruction	Carcinoma head of pancreas*	5	16.0, 8.3, 20.0, 26.0, 10.0	3
	Carcinoma gallbladder*	2	>10, 30.5	2
	Carcinoma common bile duct*	1	18.0	1
	Stone in common bile duct*	2	7.7, 17.5	0
	Stricture of common bile duct*	1	13.6	0
Cholescintigram characteristic of incomplete extrahepatic obstruction	Carcinoma head of pancreas*	1	10.1	1
	Carcinoma ampulla of Vater*	1	3.6	1
	Stone in common bile duct*	4	1.7, 1.9, 1.6, 2.7	0
	Stricture of common bile duct*	1	1.4	0
Cholescintigram consistent with either incomplete obstruction or hepatocellular disease	Stone in common bile duct†	4	5.7, 23.5, 5.4, N.A.	0
	Stricture of common bile duct*	3	2.3, 11.5, 4.4	0
	Viral hepatitis‡,§	4	18.0, 18.0, 1.5, 11.0	0
	Chronic active hepatitis‡	1	21.5	0
	Alcoholic liver disease†	4	20.5, >10, 6.0, 17.6	0
	Halothane hepatitis†	1	8.9	0
	Hepatic metastases‡	1	1.3	0
Total		36		8

\* Confirmed by operation.  
† Clinical/laboratory diagnosis.  
‡ Confirmed by biopsy.  
|| Not available.

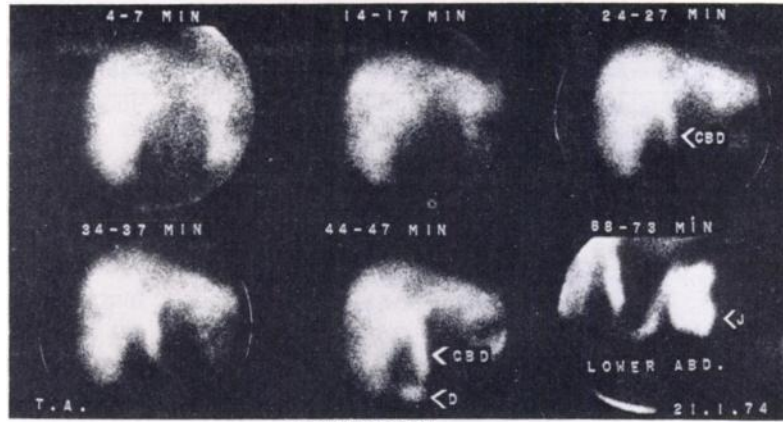
rapid biliary excretion in normal humans with delineation of the biliary tree and gallbladder within minutes of injection. Concentration of the radiopharmaceutical in the bile is sufficient to allow imaging of the common bile duct and crude differentiation between ducts of normal and increased caliber. The renal route of excretion of  $^{99m}\text{Tc-PG}$  is normally inconspicuous but may predominate over the hepatobiliary route in biliary obstruction or severe hepatocellular disease.

Eikman, et al (4) found that the gallbladder failed to accumulate radioactivity in a proportion of normal subjects who underwent  $^{99m}\text{Tc}$ -dihydrothioctic acid cholescintigraphy. This phenomenon was observed in three out of the ten control subjects in the present series. In two of these three subjects a history suggestive of chronic gallbladder disease was retrospectively obtained. Unfortunately, in none of the three was followup radiologic investigation of the biliary tree undertaken by the attending physician. Accordingly, one cannot be certain of the reason for their apparently abnormal studies. It is of interest, however, that of the eight patients with abdominal pain for investigation in whom there was nonvisualization of the gallbladder on the cholescintigram, all had pathologic conditions of the gallbladder at operation (Table 1). The use of cholecystokinin (CCK) before injection of the radiopharmaceutical, as suggested by Eikman, et al (4), would almost certainly avoid the problem of nonvisualization of the normal gallbladder. A second dose of CCK given

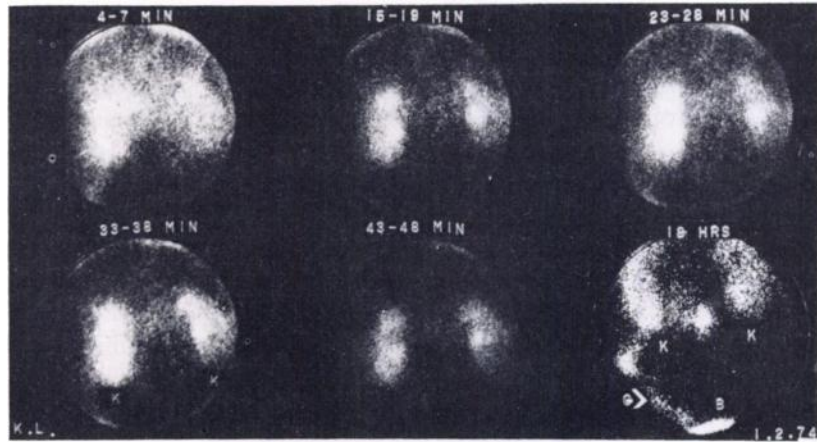
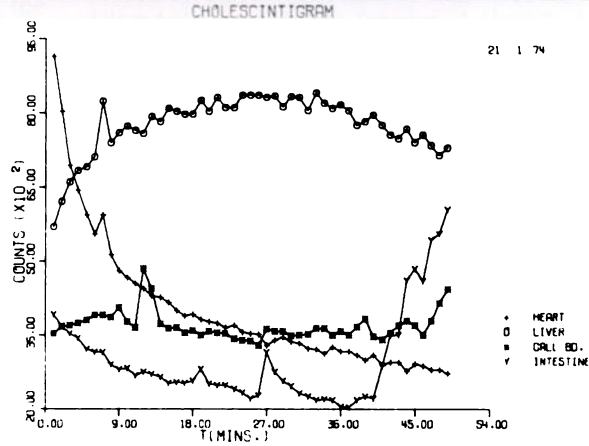
at the time of maximal gallbladder accumulation of radioactivity would serve as a test of gallbladder contractility. This application of CCK is well known in contrast cholecystography (13,14).

In the investigation of right upper quadrant abdominal pain, the cholescintigram appears able to detect reliably acute but not chronic inflammatory disease of the gallbladder. Little if any additional information, however, was provided by the cholescintigram in comparison with contrast radiologic studies in this group of patients. The higher resolution of the radiologic studies facilitates a specific diagnosis of calculous disease. (Even when the pinhole collimator was used to improve the resolution of the cholescintigram, radiologically diagnosed stones were missed by the cholescintigram.) Contrast radiologic studies are felt to be superior to the cholescintigram in the nonjaundiced patient with suspected gallbladder disease, largely for this reason.

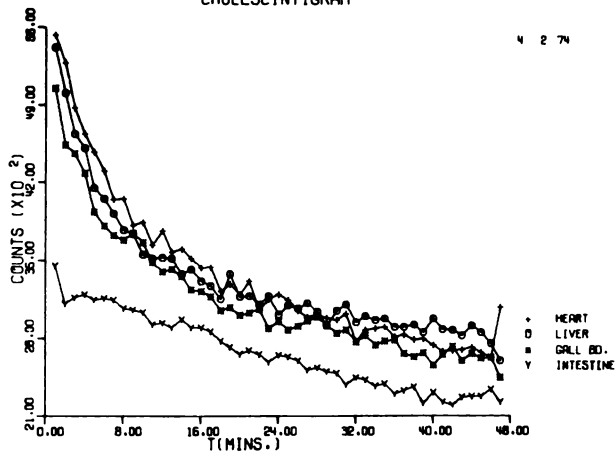
In the investigation of the jaundiced patient, the absence of gastrointestinal radioactivity at 18 hr after injection allowed a confident diagnosis of complete extrahepatic biliary obstruction to be made. Further evidence supporting a diagnosis of obstructive jaundice was provided by the presence of a defect in liver or background radioactivity due to the presence of a distended gallbladder. This is thought to be equivalent to Courvoisier's sign in clinical surgery and was found to be highly specific for neoplastic causes of biliary obstruction. (No cases of mucocele of the gallbladder were found in this series and



**FIG. 5.** Technetium-99m-PG cholecistigram in patient with incomplete biliary obstruction due to multiple common bile duct stones. Appearance of tracer in common bile duct is delayed (24-27 min) and common bile duct is distended. There is holdup of tracer in distal portion of duct and delayed entry of tracer into duodenum (44-47 min). Scintigram centered over duodenum (last frame) shows constriction in column of radioactivity in distal common bile duct. Time-activity curves show take-off of duodenal activity curve from baseline at 40 min. Scintigram and time-activity curve show absence of accumulation of radioactivity in gallbladder. At operation, gallbladder was chronically inflamed and full of stones and biliary mud. Common bile duct was distended and contained multiple stones including one large stone impacted in ampulla of Vater.



**FIG. 6.** Technetium-99m-PG cholecistigram in patient with liver failure (jaundice, fetor hepaticus, flapping tremor) due to alcoholic liver disease. Renal excretory pattern as seen in Figs. 3 and 4 again present but 18-hr scintigram shows radioactivity in gastrointestinal tract (G).





**TABLE 4. COMPARISON OF CHOLESCINTIGRAM AND CONTRAST RADIOLOGIC PROCEDURES IN PATIENTS WITH "JAUNDICE FOR INVESTIGATION"**

Patient No.	Serum bilirubin (mg/100 ml)	Cholescintigram	Oral cholecystogram	Intravenous cholangiogram	Percutaneous cholangiogram	Operative cholangiogram	Final diagnosis
12	7.7	Complete obstruction		Unsuccessful		Distended, obstructed common bile duct; stones in common bile duct	Acute on chronic cholecystitis; cholelithiasis; choledocholithiasis*
18	17.5	Complete obstruction		Unsuccessful		Stones in gallbladder and common bile duct; obstructed common bile duct	Complete common bile duct obstruction; choledocholithiasis*
29	13.6	Complete obstruction			Obstructed upper one-third of common bile duct		Complete common bile duct obstruction (stricture)*
30	2.3	Incomplete obstruction		Unsuccessful		Distended, obstructed common hepatic duct	Pinhole stricture common hepatic duct*
33	18.0	?Incomplete obstruction ?Hepatocellular disease				Normal	Viral hepatitis†
34	4.4?	Incomplete obstruction ?Hepatocellular disease		Poor dye concentration but normal diameter common bile duct		Complete common bile duct obstruction at ampulla	Acute on chronic cholecystitis, choledocholithiasis Intermittent common bile duct obstruction*
36	1.9	Nonfunctioning gallbladder; incomplete obstruction; distended common bile duct	Unsuccessful	Unsuccessful‡			Cholelithiasis, choledocholithiasis; intermittent common bile duct obstruction†
42	—	Incomplete obstruction; distended common bile duct				Distended common bile duct with multiple stones	Choledocholithiasis, partial obstruction*
61	1.6	Incomplete obstruction; distended common bile duct		Normal (2 weeks after cholescintigram)			Choledocholithiasis; intermittent common bile duct obstruction†
62	23.5	?Incomplete obstruction; ?hepatocellular disease	Unsuccessful				Choledocholithiasis; intermittent common bile duct obstruction†
65	26.0	Complete obstruction; negative gallbladder shadow				Distended, obstructed common bile duct	Complete common bile duct obstruction (carcinoma head of pancreas)*
74	3.6	Incomplete obstruction; negative gallbladder shadow				Distended, obstructed common bile duct	Partial common bile duct obstruction (carcinoma ampulla of Vater)*
78	5.4	?Incomplete obstruction; ?hepatocellular disease	One radiolucent stone in gallbladder				Cholelithiasis, probable transient obstruction due to common bile duct stone†

\* Confirmed by operation. † Clinical/laboratory diagnosis. ‡ Intravenous cholangiogram 2 months later showed incomplete common bile duct obstruction due to stone, and nonvisualization of gallbladder.

this condition should be kept in mind as a possible cause of false-positive "scintigraphic Courvoisier's sign." However, patients with mucocoele of the gallbladder are usually not jaundiced.)

Since the absence of gastrointestinal radioactivity is critical for a diagnosis of complete biliary obstruction, it is important that there be negligible  $^{99m}\text{TcO}_4^-$  in the radiopharmaceutical preparation. Routine chromatography of the  $^{99m}\text{Tc}$ -PG used in these patient studies has shown a maximum of 2% of the radioactivity present in the  $^{99m}\text{TcO}_4^-$  form. Some of this  $^{99m}\text{TcO}_4^-$  is undoubtedly secreted into the gastrointestinal tract but it has never been visible in the 18-hr scintiphotos of patients with complete biliary obstruction and is therefore not a source of confusion.

In patients with incomplete biliary obstruction, radioactivity is excreted, usually with a delayed time course, into the gastrointestinal tract. Consequently, incomplete obstruction may be difficult to differentiate scintigraphically from hepatocellular disease unless a "scintigraphic Courvoisier's sign" or distended common bile duct is seen on the cholescintigram.

In the jaundiced patient, cholescintigraphy with  $^{99m}\text{Tc}$ -PG appears to offer some advantages over contrast radiologic techniques. The latter are said to be unsuccessful where the serum bilirubin is over 2 mg/100 ml. In this series contrast radiologic studies were unsuccessful with bilirubin levels down to 1.9 mg/100 ml and were successful only when the jaundice was intermittent and the study was performed between attacks. Admittedly, where the contrast radiologic techniques were unsuccessful, the early phase  $^{99m}\text{Tc}$ -PG study was also usually unsuccessful (in that the  $^{99m}\text{Tc}$ -PG was excreted by the renal route and no radioactivity was observed in the biliary tree or gastrointestinal tract). It is in the ability to derive useful information at 18 hr after injection that the cholescintigram appears to have an advantage over contrast studies.

As is so often the case, therefore, the scintigraphic and radiologic studies are complementary rather than competitive. Contrast radiologic studies would appear to be appropriate in the initial workup of the nonjaundiced patient with right upper quadrant ab-

dominal pain possibly due to gallbladder disease whereas  $^{99m}\text{Tc}$ -PG cholescintigraphy would seem appropriate in the initial workup of the patient with jaundice possibly due to extrahepatic biliary obstruction.

## REFERENCES

1. KRISHNAMURTHY GT, TUBIS M, ENDOW JS, et al:  $^{99m}\text{Tc}$ -penicillamine—a new radiopharmaceutical for cholescintigraphy. *J Nucl Med* 13: 447, 1972
2. KRISHNAMURTHY GT, ENDOW JS, TUBIS M, et al:  $^{99m}\text{Tc}$ -penicillamine cholescintigraphy: comparison with oral cholecystography. *J Nucl Med* 14: 418, 1973
3. DUGAL P, EIKMAN EA, NATARAJAN TK, et al: A quantitative test of gallbladder function. *J Nucl Med* 13: 428, 1972
4. EIKMAN EA, CAMERON JL, COLMAN M, et al: Radioactive tracer techniques in the diagnosis of acute cholecystitis. *J Nucl Med* 14: 393, 1973
5. TONKIN AK, DELAND FH: Dihydrothioctic acid: a new polygonal cell imaging agent. *J Nucl Med* 15: 539, 1974
6. FLIEGEL CP, DEWANJEE MK, HOLMAN BL, et al:  $^{99m}\text{Tc}$ -tetracycline as a kidney and gall bladder imaging agent. *Radiology* 110: 407-412, 1974
7. LIN TH, KHENTIGAN A, WINCHELL HS: A  $^{99m}\text{Tc}$ -labeled replacement for  $^{131}\text{I}$ -rose bengal in liver and biliary tract studies. *J Nucl Med* 15: 613-615, 1974
8. GORIS ML:  $^{125}\text{I}$ -iodobromsulphalein as a liver and biliary scanning agent. *J Nucl Med* 14: 820-825, 1973
9. ANSARI AN, ATKINS HL, LAMBRECHT RM, et al:  $^{125}\text{I}$ -indocyanin green ( $^{125}\text{I}$ -ICG) as an agent for dynamic studies of the hepatobiliary system. IAEA-SM-185/61. International Atomic Energy Agency Symposium on Dynamic Studies with Radioisotopes in Clinical Medicine and Research, Knoxville, Tennessee, 15-19 July, 1974: to be published
10. VAN RIJK PP, DE GRAAF CN, VAN DEN HAMER CJA:  $^{131}\text{I}$ -asialo- $\alpha_1$ -acid glycoprotein, a new pharmaceutical for dynamic liver function studies. IAEA-SM-185/70. International Atomic Energy Agency Symposium on Dynamic Studies with Radioisotopes in Clinical Medicine and Research, Knoxville, Tennessee, 15-19 July, 1974: to be published
11. BAKER RJ, BELLEN JC, RONAI PM:  $^{99m}\text{Tc}$ -pyridoxylidene-glutamate: a new hepatobiliary radiopharmaceutical. I. Experimental aspects. *J Nucl Med* 16: 720-727, 1975
12. BAKER RJ, BELLEN JC, RONAI PM:  $^{99m}\text{Tc}$ -pyridoxylidene-glutamate: a new rapid cholescintigraphic agent. *J Nucl Med* 15: 476, 1974
13. NATHAN MH, NEWMAN A, MCFARLAND J, et al: Cholecystokin cholecystography. *Radiology* 93: 1-8, 1969
14. NATHAN MH, NEWMAN A, MURRAY DJ, et al: Cholecystokin cholecystography. A four year evaluation. *Am J Roentgenol Radium Ther Nucl Med* 110: 240-251, 1970