

ABNORMAL SPLEEN SCAN FOLLOWING MOPP THERAPY IN A PATIENT WITH HODGKIN'S DISEASE: CASE REPORT

Joseph D. Dickerman and John P. Clements

University of Vermont College of Medicine, Burlington, Vermont

A patient with Stage IV-A nodular sclerosing Hodgkin's disease is described who, at initial presentation, demonstrated an apparent large filling defect in the spleen by ^{99m}Tc-sulfur colloid scan. Following a 6-month course of MOPP therapy, the patient was clinically free of disease although the spleen scan remained unchanged. After laparotomy, the spleen was found to be entirely normal histologically.

Splenic scintigraphs in patients with Hodgkin's disease have been shown to correlate poorly with specimens obtained at laparotomy, yielding both false-negative and false-positive results (1). However, Glatstein and Goffinet state that "The presence of a clear-cut filling defect appears to be a reliable sign on scintigraphy of such visceral involvement" (2). We wish to report a patient with Stage IV-A nodular sclerosing Hodgkin's disease who demonstrated an apparent large focal defect in the spleen by ^{99m}Tc-sulfur colloid scanning at initial staging. Following a 6-month course of MOPP (mustard, Oncovin®, prednisone, and procarbazine) therapy the patient again demonstrated the same defect in the spleen and yet clinically and at laparotomy was found to have no evidence of disease.

CASE REPORT

KC, a 13-year-old white girl, presented to the Medical Center Hospital of Vermont with a 2-week history of abdominal pain, weight loss (not exceeding 10% of total body weight), anorexia, and pruritis.




FIG. 1. Initial spleen scintigraph (11/13/73).

Physical examination revealed a 3 × 4-cm right supraclavicular node, a 2 × 2-cm right posterior cervical node as well as small ½–1-cm nodes along the whole right posterior cervical chain. In addition, bilateral small ½–1-cm nodes were palpated in the submandibular, axillary, and inguinal regions. There was no hepatosplenomegaly. Chest roentgenogram revealed bilateral hilar and parahilar lymphadenopathy. Chest tomography demonstrated multiple, bilateral nodules. An upper gastrointestinal series was interpreted as possibly suggestive of extrinsic compression. Technetium-99m-sulfur colloid scan of the liver was normal. The spleen scan (Fig. 1), however, was interpreted as demonstrating a mass lesion in the superior aspect. Metastatic bone series and an intravenous pyelogram were within normal limits. A bone marrow biopsy was normal, and marrow aspiration revealed granulocytic hyperplasia with a myloid-to-erythroid ratio of 4:1. The total bilirubin was 0.5 mg% with 0.1 mg% direct, urinalysis was within normal limits, hemoglobin 12.4 gm%, hematocrit 36.8%, WBC 15,500/mm³ with 83% segmented forms, 7% lymphocytes, 7% monocytes, and 3% eosinophiles. The platelet count was 505,000/mm³, creatinine 0.7 mg%, SGOT 10 units (normal range, 9–22), SGPT 7 units (normal range, 3–23), prothrombin time 12.3 sec with a control of 12.4 sec, serum copper 286 µg/100 ml (normal range, 85–155), and uric acid 4.9 mg%. A biopsy of the right supraclavicular node revealed Hodgkin's disease, nodular sclerosing type. She was designated as Stage IV-A according to the Ann Arbor classification (3) and started on a 6-month course of MOPP therapy. At the end of the therapy period there was no clinical evidence of disease. A chest roentgenogram with tomography, upper gastrointestinal series, and bone marrow biopsy were normal. The serum copper was 150 µg/100 ml, the sedimentation rate 10, hemoglobin 11.4 gm%, hematocrit 34.5%, WBC 2,700/mm³ with 60% segmented forms, 32% lymphocytes,

Received Oct. 26, 1974; revision accepted Dec. 31, 1974.

For reprints contact: Joseph D. Dickerman, Dept. of Pediatrics, University of Vermont, College of Medicine, Burlington, Vt. 05401.



FIG. 2. Spleen scintigraph following a 6-month course of MOPP therapy (4/23/74).

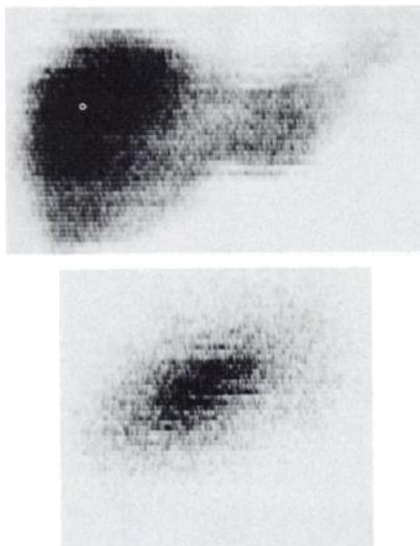


FIG. 3. Anterior (top) and left lateral (bottom) spleen scintigraphs 9 months after splenectomy (12/9/74).

6% monocytes, and 2% eosinophiles. Repeat ^{99m}Tc -sulfur colloid scan of the spleen (Fig. 2) revealed a mass lesion similar to the one previously described, demonstrating little change in appearance when compared with the original study. Laparotomy was performed with splenectomy, wedge, and core biopsy of the liver, and biopsy of high and low periaortic, iliac, and porta hepatis nodes. Transposition of the ovaries to the midline was accomplished. No gross evidence of Hodgkin's disease was present at laparotomy and no abnormality was demonstrated on histologic examination of the removed tissues. The spleen, in particular, was found to be normal on gross and microscopic examination without evidence of fibrosis, granulomas, or other disease states. Multiple sections of the spleen were cut and a hematoxylin-eosin stain was used on the microscopic specimens. The patient was started on a course of total nodal irradiation over a 3-month period to 4,000 rads. Nine months following splenectomy a repeat scan (Fig. 3) demonstrated some functioning reticuloendothelial tissue in the left upper quadrant anteriorly,

contiguous with hepatic tissue and thought to represent a normal variation in liver anatomy. No functioning reticuloendothelial tissue was identified in the posterior left upper quadrant where the spleen with its apparent focal defect was seen on the two previous studies.

DISCUSSION

Silverman, et al reported 8 out of 11 patients with Hodgkin's disease who had abnormal splenic scintigraphy yet histologically normal spleens (1). The scanning abnormalities consisted of increased concentration of radioisotope or mild-to-moderate splenic enlargement. In no instance was a focal or patchy distribution of radioactivity noted. Our patient demonstrated an apparent large filling defect in the spleen prior to laparotomy at a time when no other evidence of disease existed. Because of the unlikelihood that the spleen remained unaffected by therapy in the face of apparent improvement elsewhere, the possibility existed that the initial scan demonstrated active Hodgkin's disease whereas the second scan represented necrosis and fibrosis. Alternatively, an isolated granuloma could have been present (4). For this reason, the spleen was very carefully examined and found to be entirely normal. Although functional asplenia might possibly explain the scan results, the radioactive pattern observed in our case is not that usually seen in this condition. Followup scanning 9 months after splenectomy demonstrated uptake in the left upper quadrant anteriorly, thought to represent an extension of the left lobe of the liver. Therefore, one cannot definitely exclude the possibility that the apparent focal splenic defect seen in the two prior studies represents the superimposition of hepatic and splenic radioactivity and thus, possibly an artifact. We have no definite explanation for our finding but wish to draw attention to the fact, already well documented for other non-laparotomy staging procedures, that caution must be exercised when interpreting an apparent focal splenic defect as demonstrated by nuclide scan.

REFERENCES

1. SILVERMAN S, DENARDO GL, GLATSTEIN E, et al: Evaluation of the liver and spleen in Hodgkin's disease. II. The value of splenic scintigraphy. *Am J Med* 52: 362-366, 1972
2. GLATSTEIN E, GOFFINET DR: Staging of Hodgkin's disease and other lymphomas. *Clin Haematol* 3: 77-90, 1974
3. ROSENBERG SA, KAPLAN HS: Hodgkin's disease and other malignant lymphomas. *Calif Med* 113: 23-38, 1970
4. KADIN ME, DONALDSON SS, DORFMAN RF: Isolated granulomas in Hodgkin's disease. *N Engl J Med* 283: 859-861, 1970