

DIAGNOSTIC VALUE OF RENAL IMAGING INCIDENTAL TO BONE SCINTIGRAPHY WITH ^{99m}Tc -PHOSPHATE COMPOUNDS

Frank Vieras and Charles M. Boyd

University of Arkansas Medical Center and Veterans Administration Hospital, Little Rock, Arkansas

An assessment of the sensitivity and reliability of renal images obtained incidentally to bone scintigraphy with ^{99m}Tc -phosphate compounds is reported, and certain patterns of abnormalities associated with those renal images are described. Renal images in 119 bone scintigrams were reviewed and correlated retrospectively with radiographic procedures done within 2 weeks of the bone images. The detection rate for renal abnormalities was 97.4%; the "false-positive" rate was 8.6% and the "false-negative" rate was 2.6%. Abnormal renal images were categorized as (A) nonvisualization of one kidney (13 cases), (B) asymmetric uptake (11 cases), (C) focal decreased uptake (4 cases), (D) bilateral decreased uptake (6 cases), (E) focal increased uptake (4 cases), and (F) miscellaneous (6 cases). The first three categories were always associated with renal abnormalities. Bilaterally decreased uptake and focal increased uptake were not reliable in detecting disease. Extensive metastatic carcinoma of the prostate was noted in three of four patients with bilateral decreased uptake and normal intravenous pyelography. We conclude that renal imaging incidental to bone scintigraphy with phosphate compounds is a valuable diagnostic test. An understanding of the different patterns of abnormalities described should improve the overall reliability of the test.

Several authors have reported results of renal imaging obtained incidentally during bone scanning with ^{99m}Tc -polyphosphate and ^{99m}Tc -pyrophosphate (1-4). The significant excretion of these radiopharmaceuticals by the kidneys has allowed detection of previously unsuspected renal abnormalities.

Although the renal images show various abnormalities in patients undergoing bone scintigraphy with ^{99m}Tc -phosphate compounds, there is need to know

more about the diagnostic value of the renal findings. This paper reports our experience with this technique in an attempt to describe certain patterns of abnormalities and to identify the various diseases associated with these patterns. We attempted to assess the overall sensitivity and reliability of such renal images. We also compared the renal images obtained with the scintillation camera with those obtained with a rectilinear whole-body scanner (previous reports have only dealt with the scanner) and extended the investigation to include the use of ^{99m}Tc -diphosphonate.

METHODS AND MATERIALS

Patients selected for this study were those referred to our service for bone scintigraphy from January to November 1974 who had a renal radiographic study within 2 weeks of the bone study. One-hundred-nineteen cases met this criterion. All renal images obtained incidental to bone scintigrams were reviewed independently of the radiographs and correlated retrospectively. This correlation included i.v. pyelograms (114 cases), retrograde pyelograms (4 cases), and renal arteriograms (6 cases). The diagnostic criteria for determining the presence or absence of renal abnormalities were based on the radiographic findings. In some patients, more than one radiographic or scintigraphic study was available.

The scintigraphic images were categorized as definitely positive for renal abnormality (37 cases), questionably positive (7 cases), or negative (75 cases). Renal uptake of ^{99m}Tc -phosphate compounds was considered to be normal when it was symmetric, homogeneous, and sufficient to allow adequate visualization of both kidneys. Abnormal images were categorized into (A) nonvisualization of one kidney,

Received March 17, 1975; revision accepted June 5, 1975.

For reprints contact: Charles M. Boyd, Nuclear Medicine Service, University of Arkansas Medical Center, 4301 West Markham, Little Rock, Ark. 72201.

TABLE 1. DETECTION RATE FOR RENAL ABNORMALITIES ON BONE SCAN

	Cases positive on x-ray	Cases negative on x-ray	Total
Cases positive on scan	37	7	44
Cases negative on scan	1	74	75
Total	38	81	119

True positive = 37/44 (84.1%).
 True negative = 74/75 (98.7%).
 False positive = 7/81 (8.6%).
 False negative = 1/38 (2.6%).
 Overall accuracy = 111/119 (93.3%).

TABLE 2. NONVISUALIZATION OF ONE KIDNEY

Diagnosis	Cases
Small right kidney with poor function	1
Nephrectomy	6
Chronic pyelonephritis with poor left renal function	2
Nonvisualizing left kidney, diagnosis unknown	2
Right suprarenal neuroblastoma	1
Congenital absence of the left kidney	1
Total	13

(B) asymmetric uptake, (C) focal decreased uptake, (D) bilateral decreased uptake, (E) focal increased uptake, and (F) miscellaneous patterns.

Bone images were obtained by the use of 10–15 mCi of one of the ^{99m}Tc -stannous-phosphate compounds (polyphosphate, pyrophosphate, diphosphate), injected intravenously, and imaging was begun 2–3 hr later. The images were obtained with either a scintillation camera (Picker Dynacamera with a low-energy parallel-hole collimator) or on a rectilinear whole-body scanner (Ohio-Nuclear, Model 84, dual 5-in. whole-body scanner with 5:1 minification). The kidneys were evaluated from a 90-sec posterior view of the lumbar area using the scintillation camera, and from the posterior view of the whole-body image using the rectilinear scanner. Renal images were obtained between 2 and 4 hr after injection.

RESULTS

Using the above radiographic procedures as the criteria for a diagnosis of abnormality, 81 normal and 38 abnormal cases were found in the 119 cases studied (Table 1). Abnormal or questionably abnormal renal images were obtained in 37 of the 38 abnormal cases (detection rate 97.4%) and 74 of the 81 normal cases showed normal gamma images (91.4%). The “false-positive” rate was 8.6% and

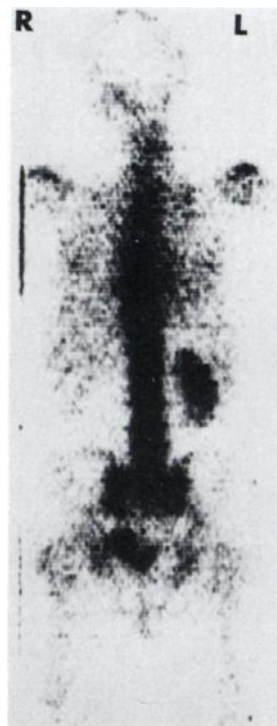

FIG. 1. Nonvisualization of one kidney in 67-year-old man 4 years after right nephrectomy for renal carcinoma. Posterior whole-body scan.

the “false-negative” rate was 2.6%. The detection rates were determined by Lusted’s method (5). By a slightly different analysis of the data, 44 bone scans were considered to show abnormal renal images, and of these 37 (84.1%) had radiographic abnormalities. Of the 75 cases considered normal on the bone scintigrams, 74 had normal radiographic images. The only instance of a renal abnormality not detectable on the bone study (“false negative”) was in a patient with a large pelvic neoplasm in whom the i.v. pyelogram showed mild calyctasis at 20 min. At 45 min, however, only minimal obstruction was evident.

Four patterns were always associated with renal abnormalities:

1. Thirteen cases had nonvisualization of one kidney (Table 2). The finding was associated with either surgical removal or non-function from disease of that kidney (Fig. 1).
2. Asymmetric renal uptake was seen in 11 cases (decreased in six kidneys and increased in four) and was quite reliable in localizing the abnormal kidney (Table 3). In one instance, the abnormality was mistakenly ascribed to the kidney showing decreased uptake whereas the abnormal kidney had increased uptake caused by obstruction. Some type of obstructive uropathy was

TABLE 3. ASYMMETRIC UPTAKE

Diagnosis	Uptake	Cases
Metastatic prostatic carcinoma with obstructive uropathy	↓*	1
Obstruction at ureteropelvic junction	↑	1
Hydronephrosis	↓	5
Hydronephrosis	↑	2
Large left extrarenal pelvis	↑	1
Nonfunctioning right kidney, massive hydronephrosis on the left	Rt. ↓ Lt. ↑	1
Total		11

↑ = increased; ↓ = decreased.
 * Abnormality erroneously ascribed to kidney showing decreased uptake. See text for discussion.

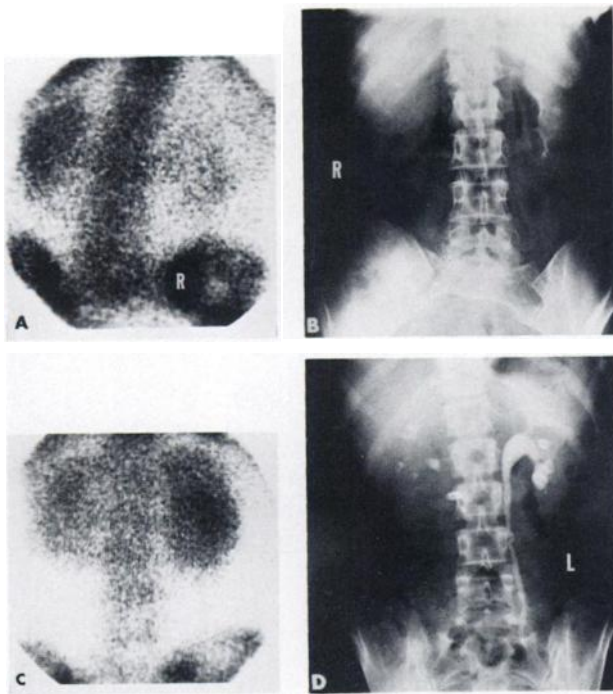
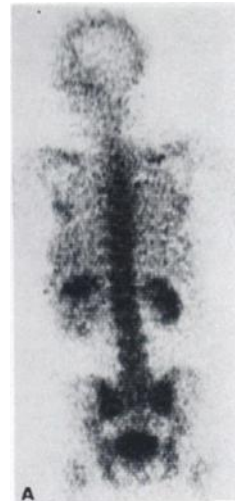

FIG. 2. Asymmetric renal uptake: (A) Woman (42 years old) with recurrent carcinoma of cervix. Posterior camera view shows decreased uptake by right kidney. (B) Intravenous pyelogram correlates with decreased renal function. (C) Woman (27 years old) with recurrent carcinoma of cervix. Increased uptake in left kidney. (D) Intravenous pyelogram shows uretero-pelvo-calyiectasis secondary to distal left ureteric obstruction.

TABLE 4. FOCAL AREAS OF DECREASED UPTAKE

Diagnosis	Cases
Tuberous sclerosis with bilateral renal hamartomas	1
Well-differentiated carcinoma, right kidney	1
Renal cyst	2
Total	4

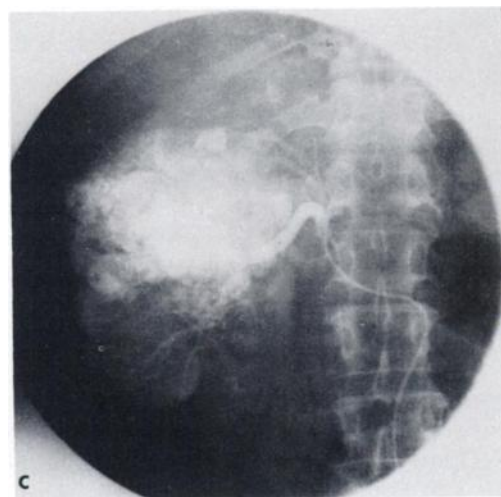
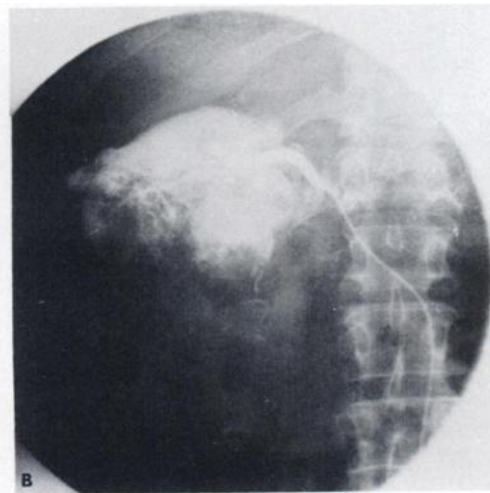


FIG. 3. Focal decreased uptake in 55-year-old man with painless hematuria. Intravenous pyelogram showed enlarged right kidney with distortion of calyceal system. (A) Posterior whole-body scan reveals nonvisualization of middle and lower poles of right kidney. Selective arteriograms of upper (B) and lower (C) branches of right renal artery, showing large hypervascular tumor mass.

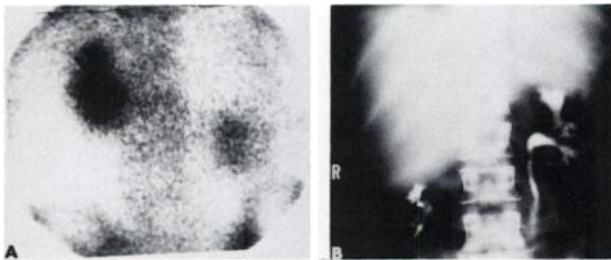


FIG. 4. Renal displacement in 40-year-old woman with 6-month history of weight loss, anorexia, and right upper quadrant pain. (A) Posterior camera image shows inferior displacement of right kidney. (B) Tomographic section of i.v. pyelogram reveals liver to be cause of displacement. Subsequent liver scan showed mass lesion pressing right lobe of liver inward and displacing it inferiorly. Mass lesion was found to be actinomycotic abscess.

TABLE 5. MISCELLANEOUS: SIZE, DISPLACEMENT	
Finding	Cases
Bilateral enlargement	1
Unilateral enlargement	2
Unilateral displacement	2
Bilateral small kidneys	1
Total	6

TABLE 6. BILATERAL DECREASED UPTAKE		
Diagnosis	Status	Cases
Prostatic carcinoma	False positive	3
Compression fracture T ₁₂	False positive	1
Bilateral hydronephrosis	True positive	2
Total		6

found in all cases of this group, with hydronephrosis (showing decreased uptake) being the most frequent. One case had increased uptake in a hydronephrotic left kidney and decreased uptake in a nonfunctioning right kidney. Figure 2 shows two examples of asymmetric renal uptake.

- Four cases had focal areas of decreased uptake (Table 4). All of these patients had space-occupying lesions of the kidneys (Fig. 3).
- There were six cases with findings of obviously enlarged, very small, or displaced kidneys (Fig. 4), all of which correlated well with the radiographic studies (Table 5).

Other patterns were found to be unreliable in detecting renal abnormalities. There were six cases with a pattern of diffuse decreased uptake in both kidneys (Table 6). Four of these cases had normal

i.v. pyelograms and thus were "false positives" (Fig. 5). Only two cases of this group, both with bilateral hydronephrosis, showed correlation with radiographic studies. Of the four "false positives," three had widespread metastatic disease from carcinoma of the prostate. Bone images in these three cases were obtained on the rectilinear scanner, two with ^{99m}Tc-diphosphonate and one with ^{99m}Tc-pyrophosphate. A patient with a compression fracture of a vertebral body studied with the scintillation camera showed a single area of markedly increased uptake at the T₁₂ vertebral level.

Increased uptake in focal areas of the kidneys was present in four cases (Table 7). One case had mild proximal obstructive disease with stasis in the renal pelvis shown on the i.v. pyelogram. The other three cases showed no radiographic abnormality and thus were "false positive" on scintigraphy. An example of this is shown in Fig. 6.

There was no significant difference between the results with the bone images done on the scintillation camera (approximately half the studies) and those done on the rectilinear whole-body scanner. There were four "false positives" in the former group, and three in the latter. The single "false negative" case was done on the scintillation camera.

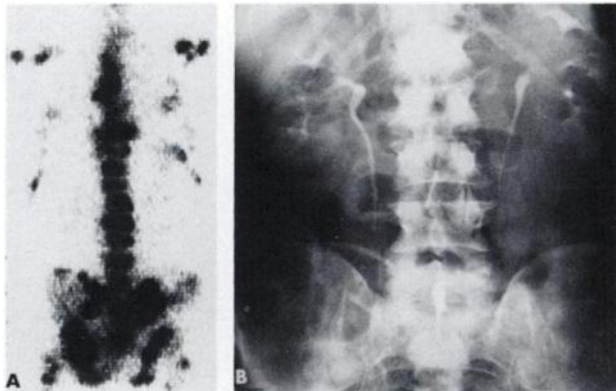


FIG. 5. Bilateral decreased uptake in 74-year-old man with metastatic prostatic carcinoma. (A) Posterior whole-body scan shows diffuse skeletal involvement and bilateral decreased renal uptake. (B) Intravenous pyelogram shows no renal abnormalities.

TABLE 7. FOCAL AREAS OF INCREASED UPTAKE		
Area of increased uptake	Correlation	Cases
Right renal pelvis	True positive	1
Both upper poles Lt > Rt	False positive	1
Both upper poles	False positive	1
Right upper pole and left renal pelvis	False positive	1
Total		4

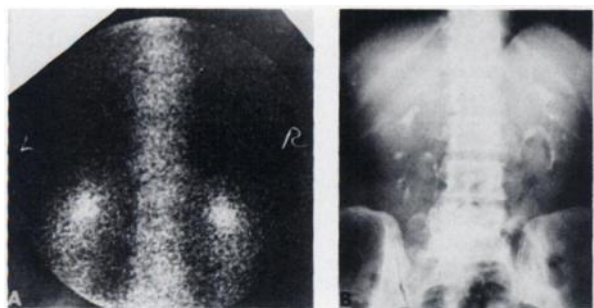


FIG. 6. Focal increased uptake in 71-year-old woman with mixed cell tumor of left thigh. (A) Posterior camera image shows focal areas of increased uptake in both upper renal poles. (B) Intravenous pyelogram disclosed no renal abnormalities.

In about half of the cases ^{99m}Tc -diphosphonate was used, and in the remainder the polyphosphate or pyrophosphate was used. No significant difference was noted between the different ^{99m}Tc -phosphate compounds.

DISCUSSION

Renal imaging obtained incidental to bone scintigraphy with ^{18}F has not been found to be reliable in detecting renal disease. Sharma, et al (6) noted that the degree of ^{18}F concentration in the kidneys bore no relation to renal disease. Although asymmetric renal accumulation of ^{18}F was often indicative of renal abnormalities, it was not possible to identify the abnormal kidney from the scan appearance. Hattner, et al (1) found renal asymmetry in ^{18}F scans to be suggestive but erratic (33% false positives). They found ^{99m}Tc -pyrophosphate bone scans to be 2.5 times as sensitive as ^{18}F scans for detecting renal abnormalities.

We approached the problem of the reliability of renal imaging incidental to bone scintigraphy somewhat differently from previous authors in that we analyzed the significance of normal renal images as well as abnormal ones. The overall accuracy of 93.3% appears to establish renal imaging during scintigraphy with ^{99m}Tc -phosphate compounds as a valuable diagnostic test. Furthermore, when the renal images are considered to be normal, the level of confidence is 98.7%, with only one case in the series being a "false negative." When the images show some abnormality, the level of confidence is 84.1%. Although not intended primarily as a renal study, the bone image certainly indicates those patients who need further diagnostic renal studies and, unless other reasons exist for such evaluation, those who do not.

The finding of bilaterally decreased uptake in patients with widespread metastatic skeletal disease was felt to be nontechnical in nature. Adequate back-

ground activity was present on the images, and if renal uptake had been at least several times that of the background, better visualization of the kidneys would have been expected. Another technical possibility is that the kidneys were out of the focal plane of the probes, but other structures on the scans did not show focal plane misalignment and both anterior and posterior views showed similar decreased uptake. For these reasons, the decreased renal uptake in these cases was felt to be real, and it suggests that in patients with metastatic carcinoma of the prostate there may be an alteration in the pharmacokinetics of the ^{99m}Tc -phosphate compounds, such as more rapid urinary clearance, increased bone accretion, or a combination of both. We believe decreased urinary clearance secondary to increased bone accretion to be the most likely causative factor. Increased bone uptake has shown a significant correlation with the level of serum alkaline phosphatase (7), which is often elevated in metastatic prostate carcinoma.

The urinary clearance of 33.3% in 4 hr in the case of ^{99m}Tc -polyphosphate, compared to 19.2% for ^{18}F , has been suggested as the cause of the better renal images obtained with the former agent (8,9). If the urinary clearance of the labeled phosphate compounds is depressed to a significant extent, the renal images obtained will not have the same diagnostic quality, and problems similar to those encountered with ^{18}F might then arise.

In those cases with diffuse metastatic bone disease, the usual bilateral decreased uptake in the kidneys may be altered by (A) the presence of intrinsic renal disease producing an absolute decrease in renal uptake, and/or (B) obstructive disease resulting in increased uptake or retention on one side. It may be difficult to identify the abnormal kidney, but the finding of renal asymmetry remains a helpful and reliable sign in inferring renal disease.

Despite normal radiographic studies, the focal areas of increased uptake in the upper renal poles found in three cases could represent localized areas of stasis, or possibly small areas of increased uptake in the renal parenchyma, which were not detected on the i.v. pyelogram. Mild or even significant renal functional impairment can go undetected on an i.v. pyelogram, masked by the dense opacification caused by the large doses of contrast material currently used (10). Thus, the real significance of this finding is not yet known.

Focal decreased uptake would be expected in space-occupying lesions of the kidney. The abnormalities found in this group correlated well with the radiographic studies. These lesions were detected by the rectilinear scanner in three cases, despite the rather poor information density commonly used on

the 5:1 minified images. One case with a renal cyst was studied on the scintillation camera.

The one "false-negative" result was obtained in a patient with a large pelvic neoplasm producing only mild unilateral obstructive changes. The inability to detect such minor change with this technique is not unexpected since we are observing only a short period in the entire renal handling of these agents.

We noted no significant difference between the various ^{99m}Tc -phosphate compounds. The kinetics of ^{99m}Tc -polyphosphate and ^{99m}Tc -diphosphonate are fairly similar (8,11), and although a qualitative difference in the renal images has been observed (11), our impression is that the overall diagnostic quality of the renal images obtained with these compounds does not differ significantly.

In conclusion, renal imaging obtained incidental to bone imaging with ^{99m}Tc -phosphate compounds has proved to be remarkably useful in detecting renal abnormality as correlated with radiographic studies. Both "false-positive" and "false-negative" rates are acceptably low. Patterns of unilateral nonvisualization, asymmetry of uptake, focal areas of decreased uptake, and abnormalities of size or anatomic location were consistent indicators of the presence of disease. On the other hand, bilateral decreased uptake and focal areas of increased uptake were not reliably correlated with renal abnormalities.

ACKNOWLEDGMENT

We wish to thank the following persons for their cooperation with this project: Karen Berry, Odesa Miles, Andrew T. Gaston, Norma Share, and Jo Anne Ellis.

REFERENCES

1. HATTNER RS, MILLER SW, SCHIMMEL D: Significance of renal asymmetry in bone scans: Experience in 795 cases. *J Nucl Med* 15: 500, 1974
2. PARK CH, GLASSMAN LM, THOMPSON NL, et al: Reliability of renal imaging obtained incidentally in ^{99m}Tc -polyphosphate bone scanning. *J Nucl Med* 14: 534-536, 1973
3. MANDEL P, SAXE B, SPATZ M: Urologic serendipity in whole body bone scanning. *Urology* 3: 283-287, 1974
4. JACKMAN SJ, MAHER FT, HATTERY RR: Detection of renal-cell carcinoma with ^{99m}Tc -polyphosphate imaging of bone. *Mayo Clin Proc* 49: 297-299, 1974
5. LUSTED LB: Decision-making studies in patient management. *N Engl J Med* 284: 416-424, 1971
6. SHARMA SM, QUINN JL: Significance of ^{18}F -fluoride renal accumulation during bone imaging. *J Nucl Med* 13: 744-746, 1972
7. ROSENTHALL L, KAYE M: Technetium-99m-pyrophosphate kinetics and imaging in metabolic bone disease. *J Nucl Med* 16: 33-34, 1975
8. SERAFINI AN, WATSON DD, NELSON JP, et al: Bone scintigraphy-comparison of ^{99m}Tc -polyphosphate and ^{99m}Tc -diphosphonate. *J Nucl Med* 15: 1101-1104, 1974
9. WEBER DA, GREENBERG EJ, DIMICH A, et al: Kinetics of radionuclides used for bone studies. *J Nucl Med* 10: 8-17, 1969
10. EMMETT JL, WITTEN DM: Methods of urographic diagnosis. In *Clinical Urography*, vol 1, 3rd ed, Philadelphia, W. B. Saunders, 1971, pp 43-52
11. KRISHNAMURTHY GT, TUBIS M, ENDOW JS, et al: Clinical comparison of the kinetics of ^{99m}Tc -labeled polyphosphate and diphosphonate. *J Nucl Med* 15: 848-855, 1974